



# Innovative Positioning for Peripherally Inserted Central Catheter Insertion on a Prone Patient

Rosanna Patrona-Aurand, MSN, RN, MM, CRNI, VA-BC

Karen A. Lovett, MS, RN, CCNS, ACNS-BC

Katherine Kochur, BSN, RN, VA-BC

St Anthony Hospital, Lakewood, CO

## Abstract

Our hospital, a 220-bed, level-1 trauma center, sees an increase in patients with acute respiratory distress syndrome (ARDS) during the winter months. To maximize an ARDS patient's lung capacity and improve mortality rates (which can be as high as 40%), it is common for a critically ill patient to remain intubated in a prone position until ventilation/perfusion rates improve. When central line access is needed, but the patient cannot tolerate staying supine for the procedure, it was hypothesized that a peripherally inserted central catheter (PICC) could be placed with the patient prone. Six patients received PICCs with a 100% success rate. The ability to place a PICC in any critically ill, prone patient can expedite the administration of fluids and drugs by the critical care team and assist them in providing optimal care.

**Keywords:** PICC, prone patient

Vascular access specialists have been trained to stand at the side of a bed during placement of a peripherally inserted central catheter (PICC). Meeting with a patient who is in a semi-Fowlers position facilitates the examination of a patient's arm(s) while utilizing an ultrasound probe to locate a viable basilic, brachial, or cephalic vein. Finding the presence of thrombi, scarring, a dialysis shunt, or an implanted port often eliminates that arm as a site for PICC placement. The patient's chest area can also be inspected for the presence of open sores, a pacemaker, a defibrillator, mastectomy scars, and signs of present and previous subclavian ports or other central venous catheters (CVCs). This assessment helps to determine whether one arm is more favorable for PICC insertion than the other. Measurement of the length from the elbow to the estimated area of the superior vena cava/right atrial junction can be done as well at this time. The prospective patient, when alert and oriented,

can also sign an informed consent while in the supine position.<sup>1</sup>

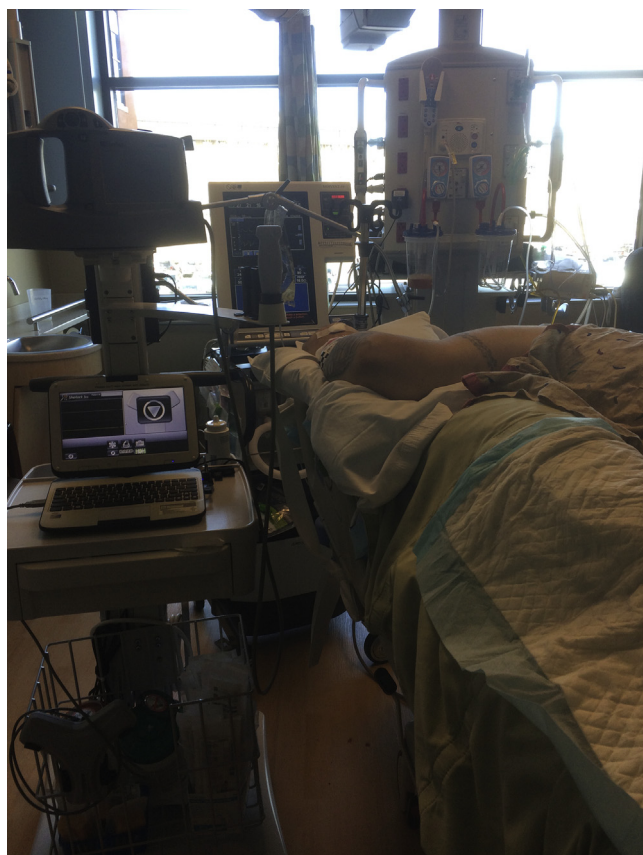Our facility is a 220-bed, level-1 trauma center with 5 intensive care units. The vascular access team places approximately 1000 PICCs and 400 midline catheters per year throughout the hospital. Occasionally, a team member is asked to place a PICC on a patient with acute respiratory distress syndrome (ARDS) who is receiving treatment in a prone position. This type of patient, seen more frequently during the fall and winter months, often cannot tolerate remaining supine long enough to place a PICC.

ARDS is characterized by pulmonary congestion, impaired oxygenation, or decreased lung compliance followed by a pulmonary insult such as sepsis, trauma, aspiration, pneumonia, or systemic injury.<sup>2</sup> The alveoli in the lungs have an increased capillary permeability and hyaline membrane formation, with a resulting edema. The accumulation of protein-rich fluid in the alveoli impairs oxygenation.<sup>3</sup> Patients with ARDS have a mortality rate as high as 40%.<sup>4</sup> As early as 1974, the prone position was recommended as a lung-protective strategy in patients with ARDS. Over the years, pronation therapy in patients with ARDS has been shown to improve regional ventilation, alveolar recruitment and oxygenation, redistribution of perfusion, recruitment of perfused tissue from dorsal regions that exceeds ventral derecruitment, and greater equality

Correspondence concerning this article should be addressed to  
[RosannaColorado@yahoo.com](mailto:RosannaColorado@yahoo.com)

<http://dx.doi.org/10.1016/j.java.2016.06.004>

Copyright © 2016 ASSOCIATION FOR VASCULAR ACCESS. Published by Elsevier Inc. All rights reserved.



**Figure 1.** This is how the patient looked upon entering his hospital room.

of ventilation and perfusion ratios.<sup>2,4,5</sup> More importantly, the prone position in patients with severe ARDS has been used to improve the survival rate.<sup>2,5-9</sup>

It had been the custom of our vascular access team to ask a prone patient's intensive care (ICU) nurse to advise us of a window of opportunity for PICC placement. As soon as the patient built up stamina to tolerate supine positioning for an hour, our team would be notified to place the PICC. However, occasionally while in the midst of the procedure, an ICU nurse would run into the room and implore us to complete the procedure more quickly due to patient deterioration. This would cause the vascular access team member a significant amount of stress, especially because this type of patient often had poor venous access to begin with.

One of the authors was asked by an ICU physician to try placing a PICC while the acutely ill patient remained in a prone position. This presented the challenge of maintaining maximal barrier precautions while choosing the correct anatomic vessel for cannulation. The insertion process was successful and 5 subsequent PICC insertions were accomplished on prone patients over the past year by 2 of the authors.

#### Case Study of a Prone Patient Needing Central Line Access

Why wait until a prone patient is supine? The following case history will illustrate why prone placement can be an

excellent choice. The case study has been approved by our institution's institutional review board.

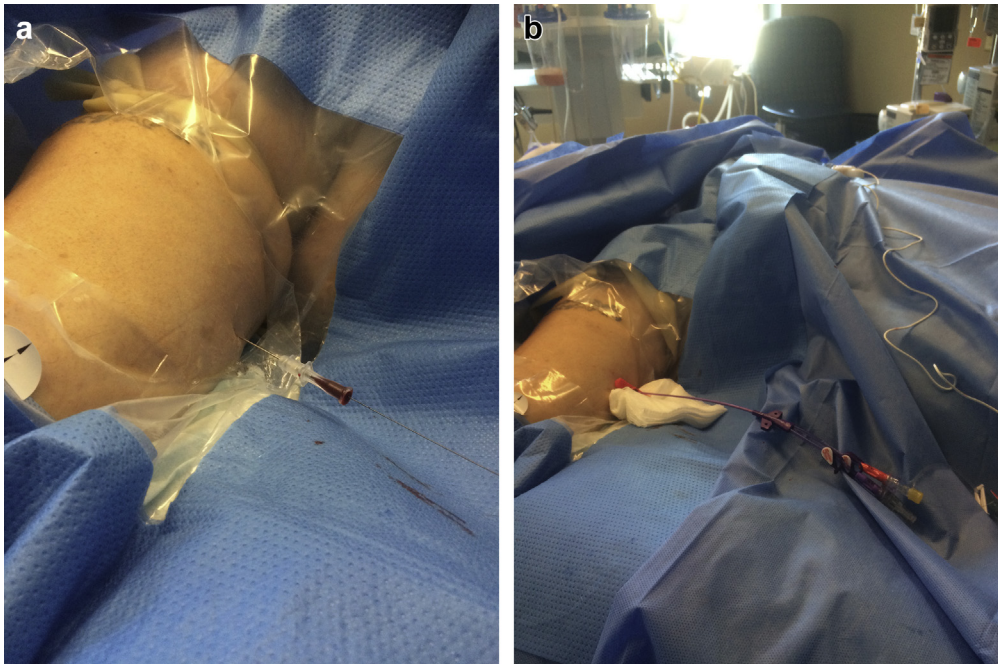
The patient was a 48-year-old morbidly obese man who weighed 371 lb (168 kg), was 6-ft tall (183 cm), and had a body surface area of 2.77 m<sup>2</sup>. He had just finished a course of oral antibiotics at home for community-acquired pneumonia, and was still feeling poorly. The ambulance personnel who arrived at his home found the patient ashen and hypoxic, and placed a nonrebreather oxygen mask on him running at 15 L/min. An 18-g peripheral intravenous line (PIV) was placed in his left antecubital fossa. His comorbidities included hypertension, type 2 diabetes, gout, chronic pain, and a previous ablation for atrial fibrillation.

He arrived at our hospital's emergency room at 10:00 PM and was diagnosed with severe hypoxic respiratory failure. Initially hypertensive at 160/100 mm Hg, he was in a sinus rhythm with unifocal premature ventricular contractions. He was afebrile at 97.0°F (36.1°C). At 11:00 PM he was sedated, intubated without incident, and placed on a ventilator. Another PIV was inserted into his right hand.

Intravenous medications administered through the patient's 2 PIVs over the next several hours included piperacillin-tazobactam, vancomycin, methylprednisolone, fentanyl citrate, propofol, hydromorphone, vecuronium, iopamidol (for a computerized axial tomography scan), etomidate,



**Figure 2.** A view of the patient's left arm, with the patient prone.

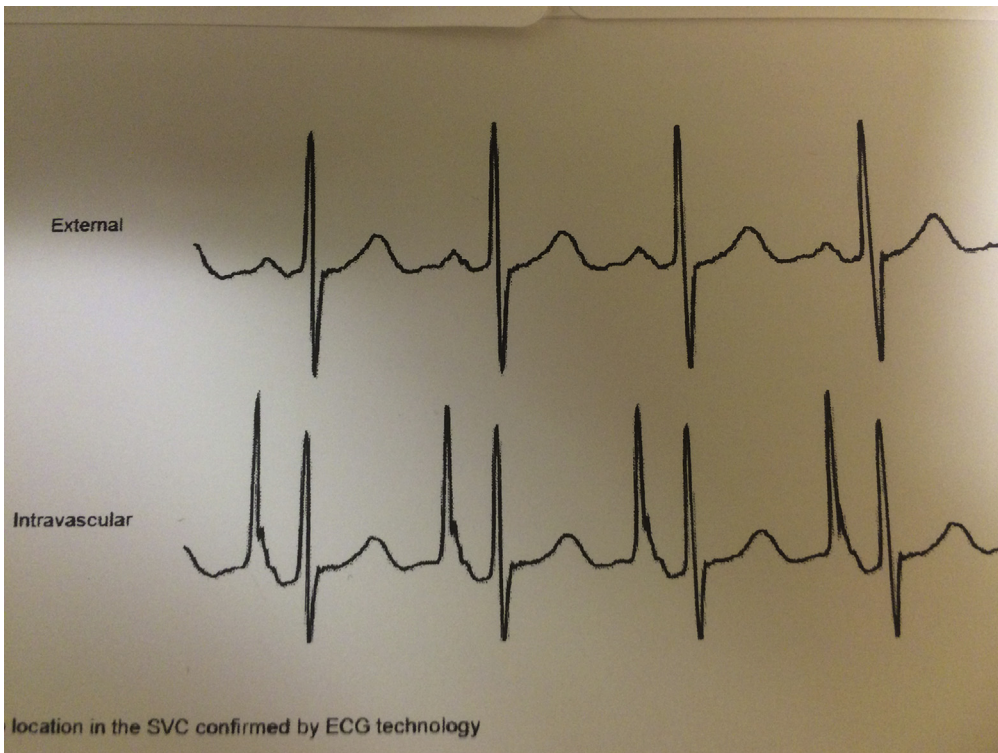


**Figure 3.** a, The left basilic vein was easily accessed using the modified Seldinger technique. b, A dual lumen peripherally inserted central catheter was inserted through a 5F dilator.

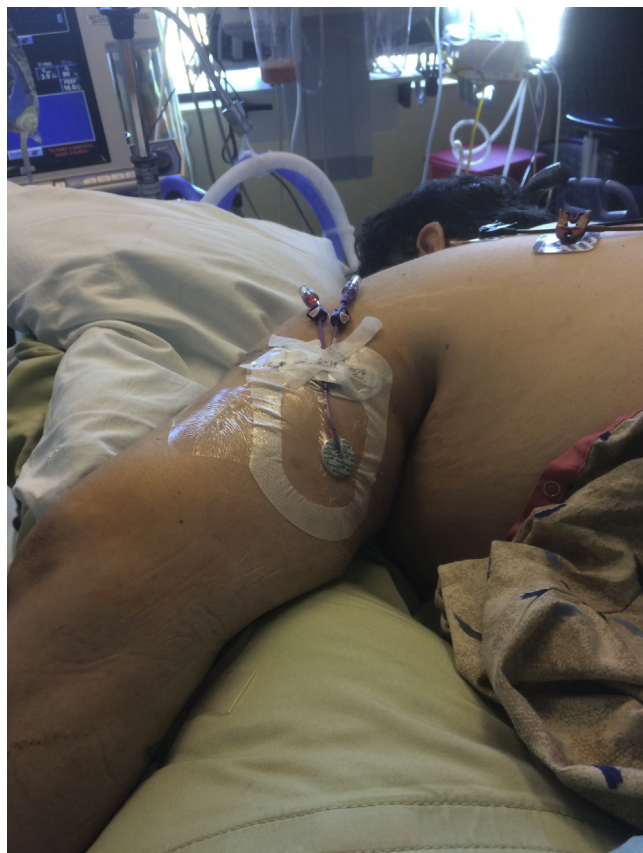succinylcholine, and midazolam. Femoral central line access was contemplated initially but the patient had an extremely large pannus. Subclavian line insertion was then considered but was believed to be too dangerous, given the patient's body habitus and underlying obstructive lung disease.

At 2:00 AM the attending physician attempted to place a right internal jugular (IJ) central venous catheter (CVC).

Maximal barrier precautions were employed. The patient's neck was short with a lot of soft tissue present. The IJ was visualized by ultrasound and cannulated, using the Seldinger technique. The wire was difficult to thread past 10-15 cm and, after numerous attempts to reposition, was removed. The right IJ was cannulated a second time and the central line was inserted. However, the follow-up radiograph



**Figure 4.** A printout from the navigation device, showing the patient's electrocardiogram tracing above and the intravenous electrocardiogram tracing below, displaying a maximal P-wave, which confirmed superior vena cava placement.



**Figure 5. The peripherally inserted central catheter dressing at the completion of prone placement.**

demonstrated that the CVC was tracking down the patient's right arm instead of the expected location in the superior vena cava. The right IJ was removed.

A new attempt was made into the patient's left IJ. Again, at 10-15 cm, the wire could not be passed. An arterial line was also attempted, but was unsuccessful. At 4:30 AM (6.5 hours after admission to the emergency department) a decision was made to pronate the patient in his ICU bed due to his deteriorating respiratory status.

Shortly after the arrival of the vascular access team at 9:00 AM, an order to place a PICC came across the printer. Upon entering the patient's room to assess the situation, the patient was positioned as shown in Figure 1.

The patient's left arm, on a pillow, was straightened to rest parallel to his body. An ultrasound probe was used to locate the patient's basilic vein. A navigation device was placed on the patient's upper back, 2 electrodes were attached to his posterior right shoulder and posterior left axillary area, and the resulting electrocardiogram showed a sinus rhythm with occasional premature ventricular contractions. The sterile PICC tray was opened and a tourniquet was placed on the patient's arm before spreading out the maximal barrier drape (see Figure 2).

The ultrasound depth was set to 2.8 cm, and the patient's left basilic vein was easily accessed using the modified Seldinger

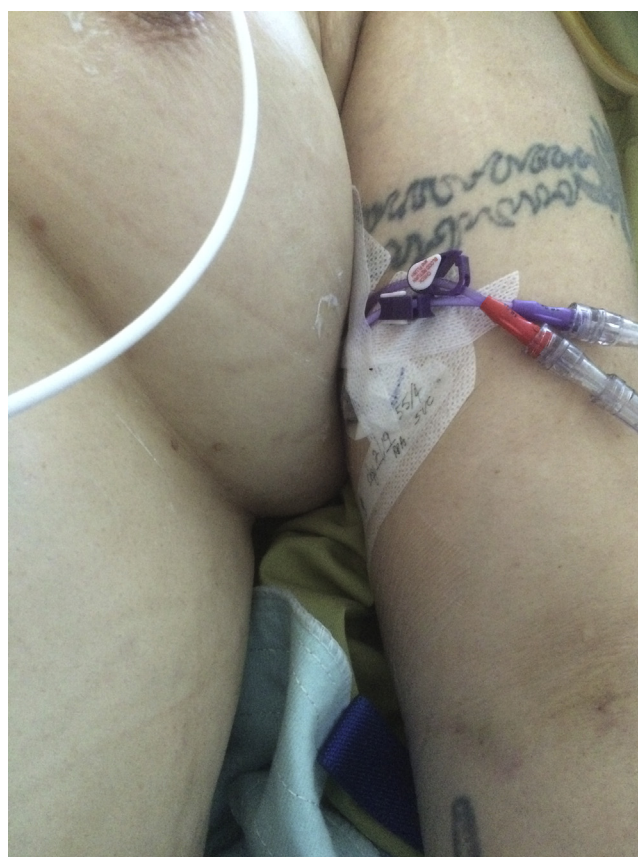technique. A dual-lumen PICC was chosen over a triple lumen only because the author anticipated problems, and the triple-lumen catheter tends to be stiffer. (See Figure 3).

Advancing the dual-lumen PICC was effortless. The navigation system worked correctly and the PICC tip was advanced until the maximal P-wave was seen on the screen (see Figure 4).

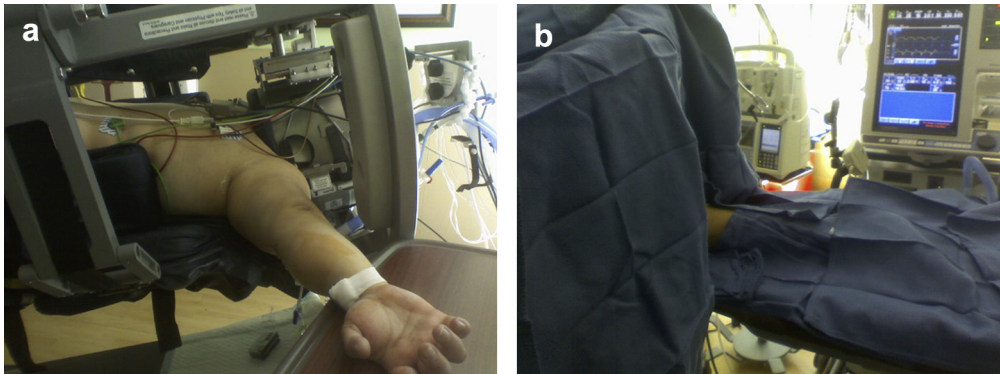
The external PICC lumen was directed toward the posterior aspect of the arm, and a sterile dressing was applied (see Figure 5).

Two days later, when the patient's lung function had improved enough to allow him to be placed supine in bed, the dressing was changed and the external lumen was directed toward the anterior aspect of his arm. The patient was discharged home 3 days later, after the PICC was removed. (see Figure 6).

Setup of the sterile field with a patient in prone positioning is similar to normal setup when the bed used is a regular hospital bed. Maximal barrier precautions include the use of facemask, cap, gown, full-length bed drape, and probe cover, in addition to sterile supplies. The patient's head can be turned toward the extended arm when feasible, and the arm can usually rest on the bed. When using a kinetic bed, which may have rails or bars, the bed may need to be unlocked to have access to the patient's arm. The arm can then be placed on a side table



**Figure 6. The same peripherally inserted central catheter site, as seen with the patient newly supine.**



**Figure 7. a, A view of the right arm of a prone patient in a kinetic bed. b, Sterile setup of the right arm of a prone patient in a kinetic bed before peripherally inserted central catheter placement.**

next to the bed, cleaned, and covered with sterile towels (see Figure 7).

Any rods or bars located above or near the PICC site can be covered before the procedure with surgical towels. The small table can also be covered with surgical drapes or towels. A measurement of estimated PICC length can be accomplished while the bed is temporarily opened, or one can make an educated guess, based on the patient's height. If the vascular access team is using a navigation system, the electrocardiogram leads can be placed near the prone patient's shoulder and side during preparation for PICC placement. Or, a postinsertion chest radiograph can be obtained while the patient is in a prone position, unless the patient is due to be rotated supine for other care.

Having the ability to place a PICC on a prone patient, whether due to severe respiratory issues or other medical problems such as decubitus ulcers<sup>10</sup> or spinal wounds, improves the quality of care for these seriously ill patients. The patient may remain prone on a normal hospital bed, or be placed in 1 of several types of rotational bed therapy.<sup>11</sup> Maintaining a previously inserted subclavian or jugular central catheter can be challenging, because the pressure on the chest and neck can occasionally cause the catheter to migrate outward.<sup>3</sup> Although PICC insertion on a critically ill prone patient may only need to be executed a handful of times per year in an acute care facility, the confidence to proceed with placement can be a critical step in the initiation or continuation of successful administration of intravenous therapy.

#### Disclosures

Authors have no conflicts of interest to disclose.

#### References

1. Corrigan A, Gorski L, Hankins J, et al. *Infusion Nursing: An Evidence-Based Approach*. 3rd ed. Norwood, MA: Infusion Nurses Society; 2009.
2. Sud S, Friedrich JO, Adhikari NK, et al. Effect of prone positioning during mechanical ventilation on mortality among patients with acute respiratory distress syndrome: a systematic review and meta-analysis. *Can Med Assoc J*. 2014;186(10):E381-E390.
3. Dirkes S, Dickinson S, Havey R, O'Brien D. Prone positioning: is it safe and effective? *Crit Care Nurs Q*. 2012;35(1):64-75.
4. Hu SL, He HL, Pan C, et al. The effect of prone positioning on mortality in patients with acute respiratory distress syndrome: a meta-analysis of randomized controlled trials. *Crit Care*. 2014;18(3):R109.
5. Guerin C, Reigner J, Richard J-C, et al. Prone positioning in severe acute respiratory distress syndrome. *New Engl J Med*. 2013;368:2159-2168.
6. Guerin C. Prone ventilation in acute respiratory distress syndrome. *Eur Respir*. 2014;23:249-257.
7. Lee JM, Bae W, Lee YJ, Cho YJ. The efficacy and safety of prone positional ventilation in acute respiratory distress syndrome: updated study-level meta-analysis of 11 randomized controlled trials. *Crit Care Med*. 2014;42(5):1252-1262.
8. Bajwa A, Arasi L, Canabal JM, Kramer DJ. Automated prone positioning and axial rotation in critically ill non trauma patients with acute respiratory distress syndrome (ARDS). *J Intensive Care Med*. 2010;25(2):121-125.
9. Beitler J, Shaefi S, Montesi SB, et al. Prone positioning reduces mortality from acute respiratory distress syndrome in the low tidal volume era: a meta-analysis. *J Intensive Care Med*. 2014;40(3):332-341.
10. Girard R, Baboi L, Ayzac L, Richard JC, Guerin C. The impact of patient positioning on pressure ulcers in patients with severe ARDS: results from a multicenter randomized controlled trial on prone positioning. *Intensive Care Med*. 2014;40:397-403.
11. Goldhill DR, Imhoff M, McLean B, Waldmann C. Rotational bed therapy to Prevent and treat respiratory complications: a review and meta-analysis. *Am J Crit Care*. 2007;16(1):50-61.