

## GUIDELINES

## European Society of Anaesthesiology guidelines on peri-operative use of ultrasound-guided for vascular access (PERSEUS vascular access)

Massimo Lamperti, Daniele Guerino Biasucci, Nicola Disma, Mauro Pittiruti, Christian Breschan, Davide Vailati, Matteo Subert, Vilma Traškaitė, Andrius Macas, Jean-Pierre Estebe, Regis Fuzier, Emmanuel Boselli and Philip Hopkins

Ultrasound for diagnostic and procedural purposes is becoming a standard in daily clinical practice including anaesthesiology and peri-operative medicine. The project of European Society of Anaesthesiology (ESA) Task Force for the development of clinical guidelines on the PERioperative uSE of Ultra-Sound (PERSEUS) project has focused on the use of ultrasound in two areas that account for the majority of procedures performed routinely in the operating room: vascular access and regional anaesthesia. Given the extensive literature available in these two areas, this paper will focus on the use of ultrasound-guidance for vascular access. A second part will be dedicated to peripheral nerve/neuraxial blocks. The Taskforce identified three main domains of application in ultrasound-guided vascular

cannulation: adults, children and training. The literature search were performed by a professional librarian from the Cochrane Anaesthesia and Critical and Emergency Care Group in collaboration with the ESA Taskforce. The Grading of Recommendation Assessment (GRADE) system for assessing levels of evidence and grade of recommendations were used. For the use of ultrasound-guided cannulation of the internal jugular vein, femoral vein and arterial access, the level evidence was classified 1B. For other accesses, the evidence remains limited. For training in ultrasound guidance, there were no studies. The importance of proper training for achieving competency and full proficiency before performing any ultrasound-guided vascular procedure must be emphasised.

This guideline is accompanied by the following Invited Commentary:

Bodenham A. Ultrasound-guided vascular access. *Eur J Anaesthesiol* 2020; 37:341–343.

From the Anesthesiology Institute, Cleveland Clinic Abu Dhabi, Abu Dhabi, UAE (ML), Intensive Care Unit, Department of Emergency, Intensive Care Medicine and Anesthesiology, Fondazione Policlinico Universitario 'A. Gemelli' IRCCS, Rome, Italy (DGB), Department of Anaesthesiology, IRCCS Istituto Giannina Gaslini, Genova (ND), Department of Surgery, Fondazione Policlinico Universitario 'A. Gemelli' IRCCS, Rome, Italy (MP), Department of Anesthesia, Klinikum Klagenfurt, Klagenfurt, Austria (CB), Anaesthesia and Intensive Care Unit, Melegnano Hospital (DV), Department of Surgical and Intensive Care Unit, Sesto San Giovanni Civic Hospital, Milan, Italy (MS), Department of Anesthesiology, Lithuanian University of Health Sciences, Kaunas, Lithuania (VT, AM), Department of Anaesthesiology, Intensive Care, and Pain Medicine, University hospital of Rennes, Rennes (JPE), Institut Universitaire du Cancer Toulouse Oncopole, Department of Anaesthesiology, Toulouse (RF), Department of Anaesthesiology, Pierre Oudot hospital, Bourgoin-Jallieu, France (EB), Leeds Institute of Medical Research at St James's School of Medicine, University of Leeds, Leeds, UK (PH)

Correspondence to Massimo Lamperti, MD, Anesthesiology Institute- Cleveland Clinic Abu Dhabi, Al Maryah Island, P.O. Box 112412, Abu Dhabi, United Arab Emirates Tel: +971(0)2 9715000; e-mail: docmassimomd@gmail.com

## CONTENTS

<b>Summary of recommendations</b> .....	345
<b>Introduction</b> .....	349
<b>Materials and methods</b> .....	350
<b>Definitions</b> .....	352
<b>Ultrasound-guided vascular cannulation in adults</b> .....	355
<b>Ultrasound-guided vascular cannulation in children</b> .....	366
<b>Ultrasound-guided vascular cannulation: training</b> .....	368
<b>Final remarks</b> .....	371
<b>Acknowledgments</b> .....	372
<b>References</b> .....	372

**Summary of recommendations**

The grading of recommendations is shown in bold type.

**Ultrasound-guided cannulation in adults**

- (1) We suggest following a step-wise approach for ultrasound-guided vascular access device placement which includes: preprocedural ultrasound evaluation of the vessel; recognition of possible local disease; ultrasound-guided real-time puncture; verification of the direction of guidewires and catheters into the vessel towards the superior vena cava for centrally inserted central catheters or towards the inferior vena cava for femoral or groin catheters; verification of the correct position of the catheter tip; detection of possible postprocedural early and late complications (**2B**).

**Ultrasound-guided cannulation of the internal jugular vein**

- (1) The quality of evidence on which to base recommendations is generally weak, with randomised controlled trials that have a high degree of heterogeneity due to the different patient populations, settings and operators performing the procedures.
- (2) We recommend the use of ultrasound-guidance for internal jugular vein cannulation in adults, as it is safer in terms of reduction of overall complications, it improves both overall and first-time success, and it reduces the time to successfully puncture and cannulate the vein (**1B**).
- (3) In terms of safety and efficacy, the use of an out-of-plane approach is similar to the in-plane approach when ultrasound guidance is used for internal jugular vein cannulation (**2A**).

**Ultrasound-guided cannulation of the subclavian vein**

- (1) The quality of evidence on which to base recommendations is generally weak, with data from

clinically heterogeneous randomised controlled trials that have some methodological problems.

- (2) We recommend the use of ultrasound-guidance for subclavian vein cannulation in adult patients, as it is safer, and it reduces the incidence of both failures and overall complications when compared with the landmark technique (**1C**).

**Ultrasound-guided cannulation of the axillary vein**

- (1) The quality of evidence on which to base recommendations is generally weak, with data from only a few, small, clinically heterogeneous randomised controlled trials.
- (2) We recommend the use of ultrasound-guidance during axillary vein cannulation, as it reduces the risk of major complications and increases the rate of first-time success when compared with the landmark technique (**2A**).

**Ultrasound-guided cannulation of the femoral vein**

- (1) The quality of evidence on which to base recommendations is weak, with data from only small randomised controlled trials and cohort studies with high heterogeneity and some methodological problems.
- (2) We recommend the use of ultrasound-guidance for cannulation of the femoral vein (or other veins of the groin) in adults, as it is safer, it reduces the incidence of major complications, it improves the success rate and it reduces the time to successful cannulation (**1C**).
- (3) We also recommend the use of ultrasound guidance for cannulation of the femoral vein (or other veins of the groin) in adults, as it may indirectly decrease infectious and thrombotic complications by reducing the likelihood of some risk factors (e.g. haematoma) related to the puncture (**1C**).

- (4) We suggest considering ultrasound-guided puncture of the superficial femoral vein at the mid-thigh to enable an exit site in a well tolerated area, reducing the risk of infection and thrombosis (2C).
- (5) We recommend out-of-plane puncture of the femoral vein using a short-axis view. A short-axis view allows a panoramic view of arteries and nerves and so helps to avoid inadvertent damage to these structures (1C).

#### **Ultrasound-guided cannulation of any peripheral vein during emergency or elective situations**

- (1) The quality of evidence on which to base recommendations is weak, with data from only small randomised controlled trials and prospective cohort studies with high heterogeneity.
- (2) We recommend adopting and applying a tool for the assessment of difficult peripheral venous access to enable early identification of those patients who may benefit from ultrasound-guided peripheral vein cannulation (1C).
- (3) We recommend the use of ultrasound guidance for peripheral vein cannulation in adults with moderate to difficult venous access, both in emergency and elective situations, as it is safer and more effective in terms of a reduction of complications, improved overall success rate and reduced time to achieve vascular access (1C).
- (4) We recommend the use of ultrasound scanning before peripheral vein cannulation in order to evaluate the location of a vein as well as its diameter and depth. This will enable the choice of the most appropriate length and diameter of peripheral vascular access device and the safest puncture site, so as to reduce the risks of accidental dislodgment and extravasation, phlebitis and thrombus formation (1C).
- (5) We recommend routine use of ultrasound guidance for peripherally inserted central catheter placement, taking care that the exit site is located at the mid arm level (1C).

#### **Ultrasound-guided cannulation of any central vein for long-term central vascular devices**

- (1) The quality of evidence on which to base recommendations is weak, with data from only small randomised controlled trials with high heterogeneity.
- (2) We recommend ultrasound guidance for placement of long-term vascular access devices, as it has been shown to significantly reduce early mechanical complications (arterial puncture, haematoma, pneumothorax, haemothorax) (1C).
- (3) We recommend ultrasound guidance for placement of long-term vascular access devices, as it has been shown to be cost-effective by indirectly reducing complications such as catheter-related thrombosis and catheter-related infections (1C).

- (4) We recommend ultrasound-guided puncture of the axillary vein at the thorax for long-term central vascular access device placement, as it has been shown to reduce the risk of pinch-off syndrome (1C).
- (5) We recommend ultrasound guidance for catheter tip location and tip navigation to avoid primary malposition (1C).
- (6) We recommend preprocedural sonographic evaluation of all possible venous options for long-term vascular access device placement to plan and choose the safest approach (1C).
- (7) We recommend ultrasound for timely diagnosis of all potentially life-threatening complications (pneumothorax, haemothorax, cardiac tamponade and so on) after central venipuncture, as it has been shown to be more accurate and faster than a chest radiograph (1B).

#### **Ultrasound-guided cannulation of an artery during elective procedures**

- (1) The quality of evidence on which to base recommendations is generally weak, with relatively few randomised controlled trials that have a high degree of heterogeneity.
- (2) We recommend the use of ultrasound guidance for radial artery catheterisation in all adult hypotensive, hypovolaemic and haemodynamically unstable patients, and in those with vascular diseases and small arteries with a weak and/or thin pulse, as it has been shown to be more effective in reducing complications, the time to successful cannulation and the number of attempts, and in increasing overall success and first-time success rate (1B).
- (3) We recommend the use of ultrasound guidance in all adults needing femoral artery catheterisation, as it has been shown to be safer by reducing major and minor complications, and it increases both overall success and first-time success rates, and reduces the time to successful cannulation (1B).
- (4) Use of a short-axis view out-of-plane approach is not superior to a long-axis view in-plane approach when ultrasound guidance is used for radial artery catheterisation (2A).
- (5) Before radial artery catheterisation, we suggest a modified Allen's test is performed using duplex ultrasonography and colour-doppler to evaluate ulnar artery collateral blood flow: absence of reverse flow in the superficial palmar branch in the hand during radial artery compression, or absence of flow in the dorsal digital artery to the thumb during radial artery compression represent contraindications to radial artery catheterisation (2C).
- (6) The catheterisation of a small radial artery is not recommended, as it is associated with the development of a clinically relevant pressure gradient (central to radial) in the course of (cardiac) surgery. Thus, values obtained by invasive blood pressure

measurement in a small radial artery can be falsely low (2C).

#### **Ultrasound for confirmation of the correct position of the central venous catheter tip in any patient for any elective or emergency situation**

- (1) The quality of evidence on which to base recommendations is generally weak, with relatively small randomised controlled trials and prospective cohort studies that have a high degree of heterogeneity.
- (2) When an intracavity electrocardiogram is not applicable, we recommend using real-time ultrasound to detect and prevent central venous catheter malposition, as it has been shown to be well tolerated, feasible, quickly performed and interpreted at the bedside, and it is more accurate and faster than chest radiograph (1C).
- (3) We recommend combining and integrating vascular ultrasound (to assist in navigating the tips of guidewires and central venous lines) with transthoracic echocardiography (for tip location) (1C).

#### **Ultrasound for verification of immediate postprocedural life-threatening complications following central venous cannulation**

- (1) The quality of evidence on which to base recommendations is generally weak, with prospective cohort studies with a high degree of heterogeneity.
- (2) We recommend performing pleural and lung ultrasound (PLUS) to rule out potential pleural-pulmonary complications (mainly pneumothorax) soon after the procedure in any difficult puncture of the subclavian or axillary vein and, particularly, if the patient complains of shortness of breath or discomfort that worsens after catheter placement (1B).
- (3) We recommend using PLUS to monitor the development of a confirmed pleural-pulmonary complication or for follow-up of treatment (1B).
- (4) We recommend ultrasound for diagnosis and follow-up of catheter-related thrombosis (1C).

#### **Ultrasound-guided cannulation in children**

- (1) For vascular access device placement in paediatric patients, we suggest the global use of ultrasound to assist all steps of the procedure that include preprocedural ultrasound evaluation of all possible options; recognition of possible local disease; ultrasound-guided real-time puncture; verification of the direction of guidewires and catheters in the vessel, and onwards towards the superior vena cava for centrally inserted central catheters, or onwards towards the inferior vena cava for femoral or groin catheters; verification of the correct position of the catheter tip; detection of possible postprocedural early and late complications (2B).

#### **Ultrasound-guided cannulation of the internal jugular vein in children**

- (1) The quality of evidence on which to base recommendations is generally weak, with relatively few small randomised controlled trials and prospective cohort studies that have a high degree of heterogeneity.
- (2) We recommend the use of ultrasound guidance for internal jugular vein cannulation in children, as it increases the success rate and reduces both the time to successful cannulation and the incidence of complications (1B).

#### **Ultrasound-guided cannulation of the brachiocephalic vein in children**

- (1) The quality of evidence on which to base recommendations is generally weak, with relatively few small prospective cohort studies that have a high degree of heterogeneity and some methodological problems.
- (2) We recommend ultrasound guidance for brachiocephalic vein cannulation only when performed by experts (1C).

#### **Ultrasound-guided cannulation of the femoral vein in children**

- (1) The quality of evidence on which to base recommendations is generally weak, with relatively few randomised controlled trials that have a high degree of heterogeneity.
- (2) We recommend the use of ultrasound guidance for femoral vein cannulation in children, as it increases the success rate (1C), with a tendency to reduce the risk of complications, without reducing the time of successful cannulation.

#### **Ultrasound-guided cannulation of the radial artery in children**

- (1) The quality of evidence on which to base recommendations is generally weak, with relatively few randomised controlled trials that have a high degree of heterogeneity.
- (2) We recommend the use of ultrasound guidance for routine arterial cannulation in children, as it increases the success rate (1B).

#### **Ultrasound-guidance cannulation of peripheral veins in children**

- (1) Due the paucity of well conducted studies, we cannot recommend the routine use of ultrasound for cannulation of peripheral veins in paediatric patients. Some evidence suggests that the use of ultrasound by an experienced operator improves the success rate of difficult peripheral vein cannulation in children; in these circumstances, it may be of some benefit (2B).

## Training

### Generic learning/training objectives

#### *Recommendations with strong consensus*

At the completion of their training, the practitioner should be able to demonstrate

- (1) Knowledge of what ultrasound is and how it is generated.
- (2) An understanding of the relationship between the frequency used, tissue penetration and image quality.
- (3) Knowledge of the biological effects and safety of ultrasound.
- (4) An understanding of the basic principles of real-time and Doppler ultrasound including colour flow and power Doppler.
- (5) Selection of the most appropriate transducer for different examinations.
- (6) Adjustment of ultrasound machine settings to optimise image quality.
- (7) Adjustment of transducer pressure, alignment, rotation and tilting to optimise image quality.
- (8) Identification of arteries, veins, nerves, tendons, muscle and fascia, bones and air-filled spaces.
- (9) Recognition of common artefacts and provision of an explanation as to how they occur.
- (10) An understanding of in-plane and out-of-plane needle visualisation techniques.
- (11) Knowledge of the benefits and limitations of in-plane and out-of-plane techniques.
- (12) The ability to minimise unintended transducer movement during needle visualisation.
- (13) The ability to maintain visualisation of the needle shaft and tip during in-plane techniques.
- (14) The ability to visualise the needle tip during out-of-plane techniques.
- (15) That they can record ultrasound images.
- (16) An understanding of the principles of patient information, consent and preparation for ultrasound-guided procedure.
- (17) Understanding the importance of practising within their own level of competence.
- (18) Procedures to minimise the risks of incorrect-site interventions.
- (19) Procedures to minimise cross-infection from ultrasound equipment.
- (20) The ability to perform ultrasound-guided procedures under sterile condition.
- (21) An understanding of the value of and techniques of continual personal audit for quality assurance and improvement.

### Learning and assessment methods for generic competencies

#### *Recommendations with strong consensus*

- (1) Learning and assessment methods should be tailored to learning objectives.

- (2) Certifying organisations should decide learning and assessment methods for each learning objective.
- (3) Training course organisers should be able to request approval for proposed learning and assessment methods from the European Society of Anaesthesiology (ESA) or relevant national societies.
- (4) Training and successful assessment in a teaching laboratory simulation environment is essential before the practitioner undertakes ultrasound-guided procedures on patients.
- (5) Assessment of competence to perform practical procedures is best undertaken using a global rating score added to a checklist of the individual components of the task.

### Specific learning/training objectives for ultrasound-guided vascular access

#### *Recommendations with strong consensus*

At the completion of their training the practitioner, in addition to achieving the generic objectives, should be able to demonstrate:

- (1) Knowledge of the sectional and ultrasonic anatomy of the neck, axillary/subclavian veins, arm (basilic vein), groin/femoral triangle, forearm (radial artery).
- (2) That they can recognise vascular disease using ultrasound, for example vessel patency, vessel occlusion, deep venous thrombosis, arterial thrombosis, pseudo aneurysm, arteriovenous fistula.
- (3) Ability to use techniques to augment the size of different veins.
- (4) Proper selection of the catheter/vein ratio.
- (5) Identification of the intravascular location of guide-wire and catheter tip.
- (6) Techniques for catheter tip navigation.
- (7) PLUS techniques for ruling out complications of central venous access.

### Training and assessment methods for an initial level of competency in ultrasound-guided vascular access

#### *Recommendations with strong consensus*

- (1) Before attempting their first directly supervised attempt for each ultrasound-guided vascular access procedure, the practitioner should have observed five ultrasound-guided procedures of that type and performed five ultrasound scans on patients scheduled for that ultrasound-guided procedure.
- (2) The practitioner undergoing training in ultrasound-guided vascular access should maintain a logbook that documents every procedure they perform.
- (3) For each ultrasound-guided vascular access procedure, the practitioner should be directly observed for at least five ultrasound-guided procedures of that type before their ability is assessed for subsequent practice with distant supervision.
- (4) For each ultrasound-guided vascular access procedure, the practitioner should be signed off as

- appropriately skilled for that procedure by an expert trainer using a global rating scale before they perform the procedure with distant supervision.
- (5) To be eligible for completion of competency-based training in both adult and paediatric ultrasound-guided vascular access, the practitioner should have performed 30 ultrasound-guided vascular access procedures of any type in a 12 months period.
  - (6) To be eligible for completion of competency-based training in ultrasound-guided vascular access, cumulative summated outcomes for key performance indicators should be within the tolerance limits of expert practice standards.
  - (7) Competence in ultrasound-guided vascular access for eligible practitioners can be signed off if they achieve satisfactory global rating scores following direct observation of a procedure by an expert trainer.
  - (8) Maintenance of competence in ultrasound-guided vascular access will require cumulative summated outcomes for key performance indicators to be within the tolerance limits of expert practice standards.
  - (9) Maintenance of competence in ultrasound-guided vascular access will require evidence of regular continuing professional development activities relevant to ultrasound-guided vascular access.
  - (10) Maintenance of competence in ultrasound-guided vascular access should be based on performance indicators only and not number of procedures.

#### **Performance indicators for ultrasound-guided vascular access procedures**

##### ***Recommendations with strong consensus***

The following are useful performance indicators for ultrasound-guided vascular access:

- (1) First-time puncture rate.
- (2) Successful completion of procedure within 30 min.
- (3) Total procedural time.
- (4) Incidence of major complications.
- (5) Incidence of overall complications.
- (6) Patient satisfaction.

#### **Criteria for defining an expert trainer in ultrasound-guided vascular access**

##### ***Recommendations with strong consensus***

An expert trainer in ultrasound-guided vascular access must be able to demonstrate

- (1) One year of independent practice in ultrasound-guided vascular access following completion of competency-based training, or
- (2) Continuous independent practice in ultrasound-guided vascular access for at least 3 years which began before the introduction of competency-based training ('Grandfather' clause).

- (3) Cumulative summated outcomes for key performance indicators to be within the tolerance limits of expert practice standards.
- (4) Evidence of regular continuing professional development activities relevant to ultrasound-guided vascular access and education/training.
- (5) For paediatric practice, should meet relevant national criteria for maintaining practice privileges as a specialist paediatric clinician in children from the relevant age group (neonate, infant, toddler, older child).

#### **Introduction**

The ESA formed a Task Force for the development of clinical guidelines on the PERioperative uSE of Ultra-Sound (PERSEUS). Although ultrasound is widely used in the peri-operative settings for many purposes, including peri-operative echocardiography, lung ultrasound, gastric ultrasound and ultrasound for difficult airway evaluation, the PERSEUS project has focused on the use of ultrasound in two areas that account for the majority of procedures performed routinely in the operating theatres: vascular access and regional anaesthesia.

These guidelines are based on the current evidence, as provided by randomised controlled clinical trials and relevant cohort studies. The evidence-based recommendations will hopefully encourage clinicians involved in these peri-operative procedures to apply the evidence in seeking clinical excellence and the best possible outcomes. One aspect to consider, which is not taken into account in these guidelines due to lack of data, is the availability of ultrasound equipment: it may take valuable time to acquire and set up the equipment and have everything ready for needle to skin (5 to 10 min or more). Hence, the use of US is still debated in emergency situations.

We are aware that financial limitations, national laws and regulatory rules may be very different from place to place, so that in some European countries, anaesthesiologists may not be able to perform ultrasound-guided procedures routinely. Nonetheless, the aim of the PERSEUS guidelines is to provide a clear definition of the procedures wherein ultrasound guidance should be considered as a standard of care, as well as those procedures or situations wherein there is insufficient evidence that ultrasound guidance should replace alternative techniques.

We are also aware that in the past, some clinicians have raised concerns about the potential legal implications of clinical guidelines.<sup>1</sup> Indeed, we feel that any guideline needs to be applied in a wise, context-sensitive manner. The final decision to follow a recommendation is in the hands of the clinician, according to each patient's needs, patient safety, available resources, local hospital policy and national laws. On the contrary, it is the responsibility of the clinician to try to adhere to evidence-based

guidelines and, should they plan not to apply any guideline recommendation, they should explain the reason to the patient and document the discussion in order to minimise the prospects of a possible negligence claim if complications occur.

The term 'point-of-care ultrasound' (POCUS) is being used more and more frequently in clinical practice.<sup>2</sup> It is commonly applied to bedside ultrasound-based procedures using portable ultrasound devices for either diagnostic or therapeutic purposes, but it applies equally to the use of ultrasound devices in the operating theatre during the peri-operative period.

As recommended by the American Institute of Ultrasound in Medicine, in order to prevent any mechanical or thermal damage to biological tissues by ultrasound, optimal total acoustic power and frequency should be set as low as possible to obtain the safest image resolution following the ALARA principles (As Low As Reasonably Achievable).<sup>3,4</sup> Two parameters, the mechanical index and thermal index, have to be below the cut-off value beyond which harmful effects might occur.<sup>3</sup> The Food and Drug Administration recommends three different cut-off values of thermal indices depending on the structures encountered in the path of the ultrasound beam: soft tissues, bone or cranium.<sup>5</sup> In the light of this evidence, ultrasound has to be used according to Food and Drug Administration recommendations and ALARA principles in order to be well tolerated and to avoid any damage.

The two main peri-operative ultrasound-guided procedures that have gained rapid popularity in the last 20 years are vascular access and regional anaesthesia. Proponents relate the improved procedure success rates when using ultrasound mainly to the ability to visualise the target (blood vessels or nerves), while real-time visualisation of the needle trajectory throughout the procedure reduces the risk of major complications such as unintended arterial puncture or pneumothorax. The goal of the PERSEUS guidelines is to review the safety and effectiveness of ultrasound-guided vascular access and regional anaesthesia, so as to provide recommendations based on the best clinical evidence or, when this is not available, on the consensus opinion of the experts enrolled in this ESA Task force.

As with any new technique in medicine, there are two main issues that have limited the use of ultrasound guidance: training and lack of availability of the new technology. Both problems will be addressed in the PERSEUS guidelines. We will introduce some key aspects of a structured training process for both vascular access and regional anaesthesia, to be used as a guide for national and local courses that enable certification of practitioners. These recommendations will help structure training in ultrasound guidance both for those currently practising ultrasound-guided procedures without a formal

proficiency certificate, and for novices in their residency training.

It is not within the scope of these guidelines to provide a financial evaluation of the impact of the use of ultrasound guidance in vascular access and regional anaesthesia, but there will be a focused analysis on potential cost-savings associated with the utilisation of these techniques.

Due to the size of the topic, the PERSEUS guidelines will be presented in two separate articles. The current manuscript will provide evidence-based recommendations for ultrasound-guided vascular access in adults and paediatric patients. A separate article will discuss the use of ultrasound in regional anaesthesia, including peripheral nerve blocks and neuraxial anaesthesia.

The following materials and methods will be focused on the first part of the guidelines, though they were basically the same for both parts of the PERSEUS project.

## Materials and methods

### Selection of the task force

Following the new policies and procedures of the ESA Guidelines Committee, an open call on the ESA website was placed and ESA members with a specific interest in peri-operative ultrasound-guided procedures were invited to apply. Six ESA members (M.L., N.D., D.G.B., E.B., J.P.E., P.H.) were selected by the ESA Guidelines Committee. A further member (A.M.) was appointed by the European Board of Anaesthesiology. The Chairman of the Task Force (M.L.) was appointed by the Task Force during a preliminary meeting held at the 2016 ESA Conference in London. After that meeting, five more members (M.P., D.V., M.S., R.F., V.T., C.B.) were selected on the basis of their specific expertise and previous publications in the fields of vascular access and regional anaesthesia and for their experience in delivering training courses around Europe on POCUS.

All members of the Task Force were involved in both parts of the PERSEUS guidelines: the role of ultrasound for peri-operative vascular access (discussed in the present manuscript) and the role of ultrasound in regional anaesthesia (discussed in a separate article).

To frame the literature search, we created separated questions with inclusion and exclusion criteria according to the PICOT process (Population, Intervention, Comparison, Outcome, Timing).<sup>6</sup> The literature search protocol and its implementation were supported and performed by a professional librarian (Janne Vendt, from the Cochrane Anaesthesia, Critical and Emergency Care Group, Herlev, Denmark).

### Literature search

We identified relevant studies by developing subject-specific search strategies, as described in Supplemental Digital Content 1, <http://links.lww.com/EJA/A278>.

The search strategies consisted of subject terms specific for each database in combination with free text terms. Where appropriate, the search strategy was expanded with search filters for humans or age. We searched the following databases from January 2010 to August 2017 for relevant studies: PubMed, EMBASE (Ovid SP), Cochrane Central Register of Controlled Trials (CENTRAL), CINAHL (EBSCO) by using Medical Subject Headings and title and abstract keywords.

We also scanned the following two trial registries for ongoing and unpublished studies: Clinical Trials (clinicaltrials.gov); WHO, International Clinical Trials Register, Search Portal.

All relevant studies published between August 2017 and September 2018 were also reviewed and considered in our analysis.

We checked the reference lists of the included studies and relevant reviews for additional studies. The search results were exported to EndNote and duplicates were removed before the retrieved publications were screened for eligibility.

### Eligibility criteria

We included the following publication types: randomised controlled trials (RCTs), prospective cohort studies, retrospective cohort studies, systematic reviews and meta-analyses and also case series with a sample size greater than 100 patients. We excluded narrative reviews, editorials, case series less than 100 patients, case reports, nonhuman studies and papers written in a non-European language. In every section, inclusion and exclusion criteria were identified on the basis of the PICOT process. We included studies on ultrasound-guided vascular access carried out on either adults or paediatric patients. All articles comparing the use of ultrasound guidance to any other technique for vascular access were selected. We applied no limitation on study duration or length of follow-up.

### Study selection

Three members of each thematic cluster (see Supplemental Digital Content 2, <http://links.lww.com/EJA/A279>) evaluated titles and abstracts identified in the literature search, verifying each publication for eligibility and relevance to the key clinical questions. A fourth reviewer resolved possible disagreements. Papers included after the abstract review process were documented in an End-Note bibliographic database for each cluster and the full-text retrieved for review. An overview of the total number of abstracts screened and articles finally included for each cluster is summarised in Supplemental Digital Content 2, <http://links.lww.com/EJA/A279>.

Two members of each thematic cluster reviewed the full-text and assessed the evidence provided by each paper, following the recommendations of the Cochrane

handbook for systematic reviews interventions.<sup>7</sup> Disagreements were resolved by consensus or by consulting a third reviewer.

### Strength of evidence

The ESA Guidelines Committee selected the GRADE system for assessing levels of evidence and grade of recommendations (GoR). This approach classifies recommendations into two levels, strong or weak (Supplemental Digital Content 3, <http://links.lww.com/EJA/A280>). A two-level grading system has the merit of simplicity. For clinicians, the two levels simplify the interpretation of the strong and weak recommendations. The PERSEUS Taskforce members were asked to define relevant outcomes across all clusters and rank the relative importance of outcomes, following a process proposed by the GRADE group. After selecting the relevant papers for each cluster, one member per group – expert in the use of RevMan and GRADEPRO – conducted the final grading of the papers. All relevant results in RevMan are reported as Supplemental Digital Content 4, <http://links.lww.com/EJA/A281> for each cluster.

For training in ultrasound guidance, there were no studies. In this situation, we used the RAND method with a modified Delphi process. We adapted the RAND/UCLA Appropriateness Method for enabling expert consensus<sup>8</sup> using iterative Delphi rounds conducted online. Statements were generated by the panel in order to develop consensus on aspects of training in ultrasound-guided vascular access and regional anaesthesia where evidence was lacking, incomplete and/or of low quality. We also included statements that assessed the appropriateness, in the context of anaesthesia training, of recommendations from other organisations who have produced guidelines for training of nonradiologists in interventional ultrasound-guided procedures. In the Delphi rounds, the panel members rated the appropriateness of each statement on a scale of 1 (completely inappropriate) to 9 (completely appropriate). The median appropriateness score (MAS) was used to categorise a statement as inappropriate (MAS 1 to 3.4), of uncertain appropriateness (MAS 3.5 to 6.9) or appropriate (MAS 7 to 9). To quantify consensus, we used the disagreement index, a dimensionless variable that is independent of the size of the expert panel. The smaller the value of disagreement index, the greater is the consensus: a disagreement index more than 1 indicates a lack of consensus.<sup>9</sup> Delphi rounds were planned to continue until an a priori stopping rule was reached for each statement as follows: if MAS more than 7 or less than 4 and disagreement index less than 0.5, or if disagreement index improves less than 15% in successive rounds.<sup>7</sup> The Delphi process was managed by one author (P.M.H.).

### Round 1

Agreed statements were sent to panel members using an online questionnaire generated in Google forms. Panel



members were instructed to rate each statement on a scale of 1 (completely inappropriate) to 9 (completely appropriate) with an option not to respond to statements that were outside their expertise. Respondents were also asked to provide freehand comments, for example on the wording of the statements or to suggest additional statements.

### **Round 2 and subsequent rounds**

Raw scores and freehand comments from Round 1 were extracted from Google forms, converted into an Excel spreadsheet and de-identified. Before Round 2, panel members received their own Round 1 scores, the de-identified scores of other panel members (as raw data and summary bar charts), the calculated MAS and disagreement index values and information on how these should be interpreted.

Round 1 statements that met a stopping criterion were not included in Round 2. Other Round 1 statements were included in Round 2 unchanged or were amended based on the freehand comments from Round 1. If panel members made suggestions for additional statements in Round 1, these were included in Round 2. The Round 2 statements were formatted as an online questionnaire as for Round 1, and the panel members asked to respond to the round 2 statements as for round 1. If the stopping criteria were not met for all statements after Round 2, the process for subsequent rounds would follow that of Round 2.

A series of 92 statements, subdivided into 10 themes regarding PICOTs where scientific evidence for the use of ultrasound in vascular access and regional anaesthesia was lacking, was agreed for Round 1. Twelve out of 13 panel members responded in Round 1.

Sixty-one of the statements were rated as appropriate with MAS more than 7 and disagreement index less than 0.5. Eleven statements were not carried forward to Round 2 either because they were considered inappropriate (MAS <4 and disagreement index <0.5) or because a mutually exclusive statement met the stopping criteria for appropriateness.

Round 2 consisted of 29 statements including 13 new statements derived from freehand comments made by panel members in Round 1. All 13 panel members participated in Round 2. Nineteen statements were rated as appropriate with MAS more than 7 and disagreement index less than 0.5. One statement (Volume of local anaesthetic used is a useful performance indicator for ultrasound-guided regional anaesthesia) met a stopping criterion (disagreement index improved by less than 15% on previous round) but only achieved a MAS of 7. Ten statements were not carried forward to Round 3 because a mutually exclusive statement met the stopping criteria for appropriateness.

Round 3 was made up of just six statements, in which separate criteria for paediatric vs. adult ultrasound-guided vascular access were introduced. Twelve panel members responded. Consensus was reached on only two statements with the other four meeting stopping criteria.

### **Review process**

The ESA Guidelines Committee supervised and coordinated the preparation of guidelines. The final draft of the guidelines underwent a review process previously agreed upon by the ESA Guidelines Committee. The draft was posted on the ESA website from 5 May to 4 July, and the link sent to all ESA members, individual or national (thus including most European national anaesthesia societies). We invited comments within this 4-week consultation period. The most relevant comments have been collected from all these resources and addressed in the final version of the paper as appropriate. The Taskforce also sent the draft for review to experts external to the ESA with specific expertise and peer-reviewed publications in the specific area of interest (ultrasound guidance in vascular access). The external reviewers were contacted by the Taskforce chairman and they were asked to complete their review within 2 weeks from submission. All the appropriate comments and suggestions were used to modify the document. After final approval by the ESA guideline committee, the ESA will be responsible for publication of the guidelines and for implementation programmes for education at different levels. Finally, application of the guidelines throughout Europe will be monitored and a regular update of the guidelines is planned every 5 years.<sup>10</sup>

### **Definitions**

The main focus of the ESA Task Force was to answer the question, 'Should ultrasound be used routinely during vascular cannulation or during peripheral nerve blocks and neuraxial anaesthesia, providing local resources and expertise are available?' We first agreed, through a Delphi consensus, some definitions on the use of the ultrasound techniques, then we identified specific PICOT questions on the use of ultrasound that were answered after a revision and analysis of the literature.

#### **Definitions regarding ultrasound techniques**

As there was lack of clarity in the literature regarding definitions, this Task Force formulated some definitions.

A procedure is defined as *ultrasound-assisted* when ultrasound scanning is used to verify the presence and position of a suitable target vessel (or any anatomical variations or disease) before needle insertion, without real-time ultrasound needle guidance.

A procedure is defined as *ultrasound-guided* when ultrasound scanning is used to verify the presence and position of a suitable target vessel before skin puncture

and real-time ultrasound imaging is used to guide the needle tip into the vessel.

The *longitudinal view* or *long axis view* is an ultrasound imaging approach that describes the relationship between the plane of the probe and the axis of the vessel. In the long axis view, the plane of the probe is parallel to the long axis of the vessel.

The *transverse view* or *short axis view* is an ultrasound imaging approach that describes the relationship between the plane of the probe and the axis of the vessel. In the short axis view, the plane of the probe is perpendicular to the axis of the vessel.

The *oblique axis view* is obtained by initially locating the vessel in the short axis, followed by rotation of the probe to almost midway between the short axis and long axis views.

As regards the visualisation of the needle during the procedure, the Task Force agreed on the definition of two approaches:

- (1) the *in-plane* approach: where, regardless of the vessel view, the needle is advanced 'in-plane', that is within the plane of the array of transducer elements within the probe, that is providing a long axis view with visualisation of the whole shaft of the needle as it progresses towards the target.
- (2) the *out-of-plane* approach: where, regardless of the vessel view, the needle is advanced 'out-of-plane', that is perpendicular to the plane of the array of transducer elements within the probe, providing a short axis view of the needle, visualised as a hyperechoic dot.

### Application of ultrasound to vascular cannulation

Secure venous access for the administration of intravenous drugs and fluids is mandatory during the perioperative period and the use of ultrasound was initially proposed as a rescue technique when the traditional landmark techniques had failed. More recently, international guidelines have suggested the use of ultrasound as a primary technique because of its apparent advantages over landmark techniques. Finally, many guidelines (National Institute of Clinical Excellence,<sup>11</sup> European Society of Intensive Care Medicine,<sup>12</sup> American Society of Anesthesiology<sup>13</sup>) recommend the use of ultrasound not only for venepuncture itself but also for preprocedural scanning of the vessel and of the surrounding structures.

We have considered the use of ultrasound for the placement of all types of vascular catheter, either into a deep vein or into an artery, in both adults and children, and in both elective or emergency settings.

As the use of ultrasound is particularly common for central venous cannulation, we adopted a new

classification of central venous catheterisation according to the insertion site, as follows:

- (1) *Centrally inserted central line* is a central venous catheter inserted into a deep vein in the supraclavicular or infraclavicular area.
- (2) *Peripherally inserted central line* is a central venous catheter inserted into a deep vein of the arm (usually the basilic vein but also the brachial veins).
- (3) *Femorally inserted central line* is a central venous catheter inserted into a deep vein at the groin (either the common or the superficial femoral vein).

### General recommendations

We recommend that the above definitions be used in both clinical practice and research.

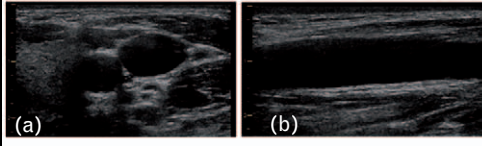
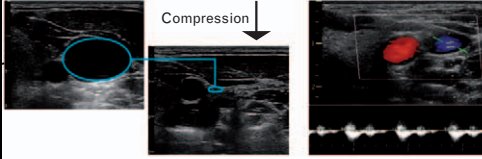
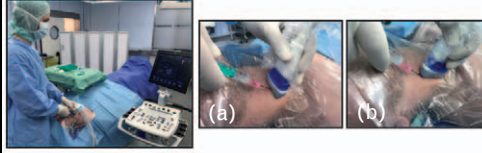
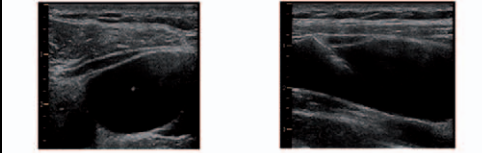
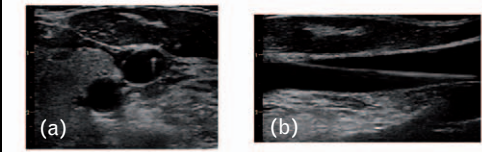
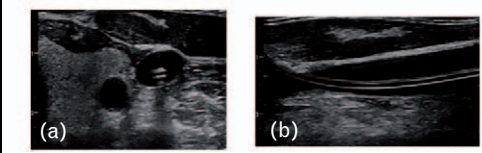
### Ultrasound-guided vascular cannulation

The use of ultrasound in vascular access placement has dramatically reduced the number of early and delayed complications and it has been suggested as a routine practice for cannulation of the internal jugular vein (IJV).<sup>14</sup> Due to the limited number of studies, the evidence is generally weak as regards the added value of ultrasound during the cannulation of other vessels,<sup>15</sup> and accordingly, our guidance will be presented along with the GRADE recommendation (Supplemental Digital Content 3, <http://links.lww.com/EJA/A280>). We will present the evidence on ultrasound when used for these more controversial sites, such as the subclavian and axillary veins, as well on other sites such as the deep veins of the arm, wherein ultrasound is now commonly used for the placement of peripherally inserted central line catheters. The benefits of ultrasound are not limited solely to the act of venepuncture, but are extended to the preprocedural detection of disease or abnormal anatomy, choice of vein<sup>16</sup> and to the timely detection of early insertion-related complications and of late complications such as catheter-related thrombosis. To avoid possible contamination of the needle entry site, there should be strict observation of the central line associated bloodstream infection prevention bundles whenever any ultrasound-guided vascular access is attempted. Few studies have considered the time spent to set up the ultrasound equipment ready for use, and so this has not been quantified. However, this panel of experts agreed that, assuming the equipment is at hand, properly trained healthcare operators take a very short time, less than 1 min, to set up the equipment ready for use.

These guidelines will hopefully help the clinician to make a rational use of ultrasound in relation to the placement of a vascular access device (Fig. 1).

Results of the meta-analyses performed on the different PICOTs are available in Supplemental Digital Content 4, <http://links.lww.com/EJA/A281>.

**Fig. 1**

I. Identify anatomy of insertion site and localization of the vein	
<ul style="list-style-type: none"> <li>• Identify vein, artery, anatomical structures</li> <li>• Check for anatomical variations</li> <li>• Use short axis (transverse; A) and long axis (longitudinal; B) view</li> <li>• Perform this step before prepping and draping of the puncture site</li> </ul>	
II. Confirm patency of the vein	
<ul style="list-style-type: none"> <li>• Use compression ultrasound to exclude venous thrombosis</li> <li>• Use colour Doppler imaging and Doppler flow measurements to confirm the patency of the vein and to quantify blood flow</li> </ul>	
III. Use real-time US guidance for puncture of the vein	
<ul style="list-style-type: none"> <li>• Use an aseptic approach</li> <li>• Use a short axis/out-of-plane (A) or a long axis/in-plane (B) approach</li> <li>• Try to the tip of the needle during the needle approach to the vein and puncture of the vein</li> </ul>	
IV. Confirm needle position in vein	
<ul style="list-style-type: none"> <li>• Confirm that the needle tip is placed centrally in the vein before the guide wire</li> </ul>	
V. Confirm wire position in vein	
<ul style="list-style-type: none"> <li>• Confirm the correct position of the guide wire in a short axis (a) and a long axis (b) view</li> </ul>	
VI. Confirm catheter position in vein	
<ul style="list-style-type: none"> <li>• Confirm the correct position of the central venous catheter in the vein in a short axis (a) and a long axis (b) view</li> </ul>	

Step-by-step approach for vascular access placement. Although this refers to ultrasound-guided catheterisation of a vein, it can be applied to any vessel.

## Ultrasound-guided vascular cannulation in adults

### Should ultrasound-guidance be used during cannulation of the internal jugular vein for central venous line placement in adults?

The IJV represents the most commonly used central vein for central venous catheter placement in the peri-operative period. Figure 2 shows the transverse view visualisation of the IJV. Existing guidelines,<sup>13,14</sup> meta-analyses<sup>17</sup> and RCTs<sup>18</sup> recommend the use of ultrasound in both elective and emergency settings but, in some of them, the recommendation is qualified by an assumption that the technology may not be available.<sup>18</sup> Five hundred and eighty-eight abstracts were screened for relevance; 235 papers were selected for analysis, but only 30 of them were finally included to inform the current guidelines.

We analysed the efficacy of ultrasound guidance when compared with landmark or other techniques.

#### Overall success

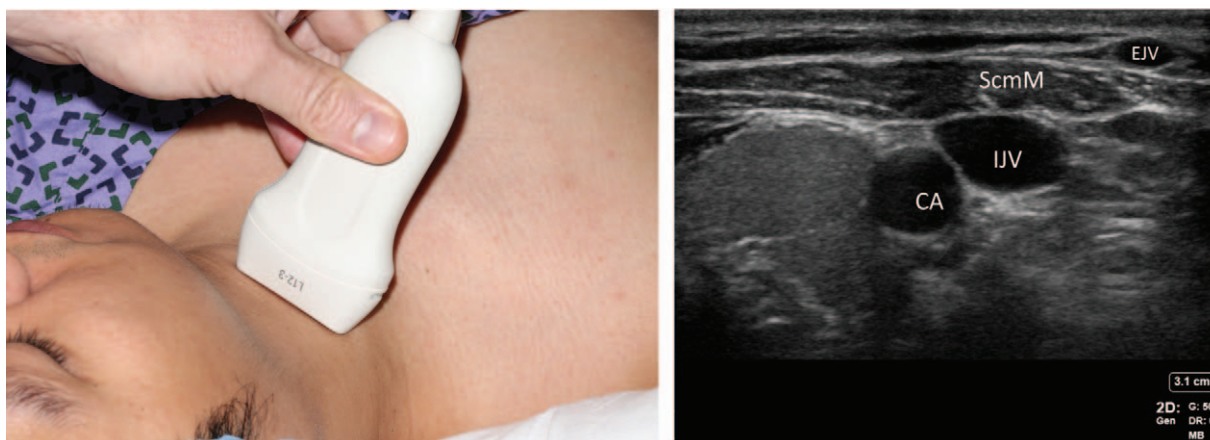
Using a random effects model, our analysis of 15 RCTs<sup>19–33</sup> and one prospective cohort study<sup>34</sup> showed that landmark-based and ultrasound-assisted cannulation techniques are less effective than ultrasound guidance, with 128 fewer successes per 1000 cannulations [relative risk (RR); 95% confidence intervals, CI]: 0.20 (0.12 to 0.34) with  $I^2$  (measure of heterogeneity) = 39%. In one of these studies<sup>30</sup> wherein the overall results of ultrasound guidance and a landmark technique were similar, the authors suggested that their findings could be explained by a lack of adequate training in ultrasound guidance. In another other large study,<sup>21</sup> in which the operators were experienced in both techniques, ultrasound guidance was superior with a 100% success rate. These findings illustrate the importance of adequate training in all

comparator techniques if equipoise is to be achieved. We note that training was not considered as an important factor for bias in previous systematic reviews and it was not possible for us to assess biases related to the levels of competency in vascular access placement.

#### Overall complications

Ultrasound is effective in reducing the rate of all insertion-related complications, including mechanical (arterial puncture, posterior wall puncture, haematoma, pneumothorax) and infectious complications. In considering the overall rate of complications, we performed a meta-analysis on 20 RCTs<sup>18–38</sup> and one prospective cohort study.<sup>20</sup> Our results revealed that, compared with the landmark or any other technique, ultrasound had a RR (95% CI) of 0.27 (0.20 to 0.35) favouring ultrasound, the equivalent of 75 fewer complications for every 1000 procedures. Our analysis revealed that major complications such as carotid puncture can be avoided when ultrasound is used by experienced as well as inexperienced operators.<sup>21,34</sup> Carotid puncture can lead to an expanding haematoma that can quickly compress the trachea producing airway obstruction and hypoxia. Not only can the use of ultrasound avoid or minimise this risk but also it can be useful for estimating the size of the haematoma. Evaluating whether there is an ongoing blood leak is useful in determining the need for interventional radiology or tracheal intubation. The studies analysed showed a consistent reduction in minor complications such as small haematomas or multiple vessel punctures when ultrasound was used. Minor complications can lead to late problems such as deep venous thrombosis and central line associated blood stream infection: multiple injuries to the skin and vein wall may increase the risk of bacterial contamination or local thrombosis.

Fig. 2



Short axis view of the right internal jugular vein in an adult patient. External view: the ultrasound probe is placed in the mid-neck area to obtain a view of the neck vessels. The head of the patient could be slightly rotated. Ultrasonographic image: CA, carotid artery; EJV, external jugular vein; IJV, internal jugular vein; ScmM, sternocleidomastoid muscle.

**First-time success**

We analysed 11 RCTs<sup>18,19,23,24,26–28,33,35,36,38</sup> in which first-time success was considered as a primary or secondary outcome. A random effects meta-analysis gave a RR (95% CI) of 0.34 (0.28 to 0.41),  $I^2 = 49%$ , favouring ultrasound: equivalent to 334 per 1000 more first-time successful cannulations compared with landmark techniques. Ultrasound-guided techniques were also more effective than ultrasound-assisted techniques. The first-time success using ultrasound guidance was extremely variable, ranging from 78.9 to 96.6%, but consistently better than with other techniques (23 to 65%). Again, these results seem to be related to the proficiency of the operators. For example, the study by Milling *et al.*<sup>28</sup> compared ultrasound guidance with other techniques in a teaching hospital wherein the operators had not received adequate training.

**Time to successful puncture**

In only five RCTs<sup>21,22,25,32,38</sup> was the time required to obtain a successful puncture of the IJV a primary or secondary outcome. The meta-analysis on these studies showed that ultrasound guidance was 2.5 s faster (95% CI, 2.55 to 2.43) than any other technique. A clear advantage of the ultrasound-guided technique was evident in the study by Karakitsos *et al.*<sup>21</sup> who found the time to successful puncture was 17.1 s (SD, 1.3) compared with 44 s (SD, 3.5) when using a landmark technique. However, these differences are of doubtful clinical relevance if we consider the overall time to complete the cannulation of the IJV and the time to set up the ultrasound equipment.

**Time to successful cannulation**

Three RCTs<sup>19,35,38</sup> and one prospective cohort study<sup>34</sup> described the total time required to perform the cannulation of the IJV when ultrasound guidance was compared with other techniques. The results from the meta-analysis revealed that ultrasound guidance was more efficient as the complete procedure took 2.17 min less (95% CI, 2.23 to 2.11). The papers analysed revealed a great variability in terms of time to complete the procedure, ranging from 4 to 19 min when using ultrasound guidance compared with 8 to 21 min using other techniques. Before drawing conclusions on this issue, we need further clinical studies with a common protocol for timing the procedure. The preparation of the ultrasound probe and the setup of the ultrasound machine should be considered in the assessed timeframe. When a central line placement is needed, the availability of an ultrasound machine ready for use will minimise the time required for IJV cannulation.

**Recommendations**

The quality of evidence on which to base recommendations is generally weak, with RCTs that have a high degree of heterogeneity due to different patient populations, settings and operators performing the procedures.

We recommend the use of ultrasound guidance for IJV cannulation in adults, as it is safer in terms of a reduction in overall complications, it improves both overall and first-time success, and it reduces the time to successful puncture and cannulation of the vein (**1B**).

In terms of safety and efficacy, the use of an out-of-plane approach is similar to the in-plane approach when ultrasound guidance is used for IJV cannulation (**2A**).

**Should ultrasound guidance be used during cannulation of the subclavian vein for central venous line placement in adults?**

The subclavian vein has been suggested as the vein of choice for central venous cannulation in patients admitted to the ICU because of a reduced risk of catheter-related infections and thromboses,<sup>39</sup> but its 'blind' puncture by landmark techniques is frequently associated with complications such as arterial puncture and pneumothorax. We analysed 588 abstracts for relevance, selected 235 papers for analysis and finally included seven papers to inform our guidelines. The ultrasound-guided technique was compared with landmark techniques, as other techniques were not used.

**Overall success**

Our random effects meta-analysis of studies published after 2005 (six RCTs)<sup>29,40–44</sup> included studies wherein the ultrasound-guided technique was used for cannulation of the subclavian vein. Our results show that landmark techniques were less effective than ultrasound guidance, RR (95% CI) 0.36 (0.24 to 0.54), equivalent to 141 fewer successes per 1000 cannulations, although the high degree of heterogeneity ( $I^2 = 62%$ ) should be noted. This finding is in line with Lalu *et al.*,<sup>45</sup> who reported a RR of 0.24 for failed cannulation. There is still a lack of agreement on the use of an infra or supraclavicular approach and on the use of ultrasound guidance in the peri-operative setting or in the ICU. For both these reasons, further studies are required to define any real advantage of USG when the SCV is preferred for central venous access.

**Overall complications**

We performed a meta-analysis on six RCTs<sup>29,40,41,43,46,47</sup> and found that, for subclavian vein cannulation, ultrasound guidance results in RR (95% CI) of 0.42 (0.31 to 0.58),  $I^2 = 56%$ : equivalent to 124 fewer major complications per 1000 cases compared with landmark techniques. Although we did not analyse every single complication in detail, our results are consistent with the previous analysis by Lalu *et al.*,<sup>45</sup> which reported arterial puncture as the main major complication, with ultrasound guidance resulting in a more than 60% reduction compared with landmark techniques. In the same systematic review,<sup>45</sup> other reported complications during subclavian vein cannulation were pneumothorax, haemothorax and

haematoma: in each case, the incidence was reduced with ultrasound guidance compared with landmark techniques. Catheter malposition may still occur with either ultrasound guidance or landmark techniques, and this seems to be related to the failure to use ultrasound for tip location and tip navigation, as will be described later in this guideline.

We did not analyse the time to successful subclavian vein cannulation or the total time taken to perform the procedure, as there were no clear data available to perform even a narrative review on these endpoints.

It should be noted that the results from our meta-analyses were greatly influenced by one study: the study by Fragou *et al.*<sup>41</sup> accounted for 33% of the weighting of our findings.

### Recommendations

The quality of evidence on which to base recommendations is generally weak, with data from clinically heterogeneous randomised controlled trials with some methodological problems.

We recommend the use of ultrasound guidance for subclavian vein cannulation in adult patients, as it is safer, and it reduces the incidence of both failures and of overall complications when compared with the landmark technique (1C).

### Should ultrasound guidance be used for cannulation of the axillary vein for central venous line placement in adults?

Cannulation of the axillary vein as an alternative to the subclavian vein gained popularity after the introduction of ultrasound guidance into clinical practice. The axillary

vein can be visualised infraclavicularly, both in short and long axis views, and it can be punctured both out-of-plane and in-plane.<sup>48–50</sup> Figure 3 shows a transverse and longitudinal view of the axillary vein. In the past, there has been some confusion between axillary and subclavian vein cannulation using the infraclavicular approach. Considering that the transition from the axillary to the subclavian vein is located at the external margin of the first rib, and that ultrasound visualisation of the first rib is often difficult because it is hidden by the clavicle, it may be difficult to determine if the cannulated vein is actually the axillary or subclavian vein, particularly when adopting an out-of-plane, short axis technique. We found 588 abstracts potentially relevant to this topic, 235 were selected for analysis and finally only two RCT studies<sup>50,51</sup> were used to inform the guidelines; a meta-analysis could not be performed.

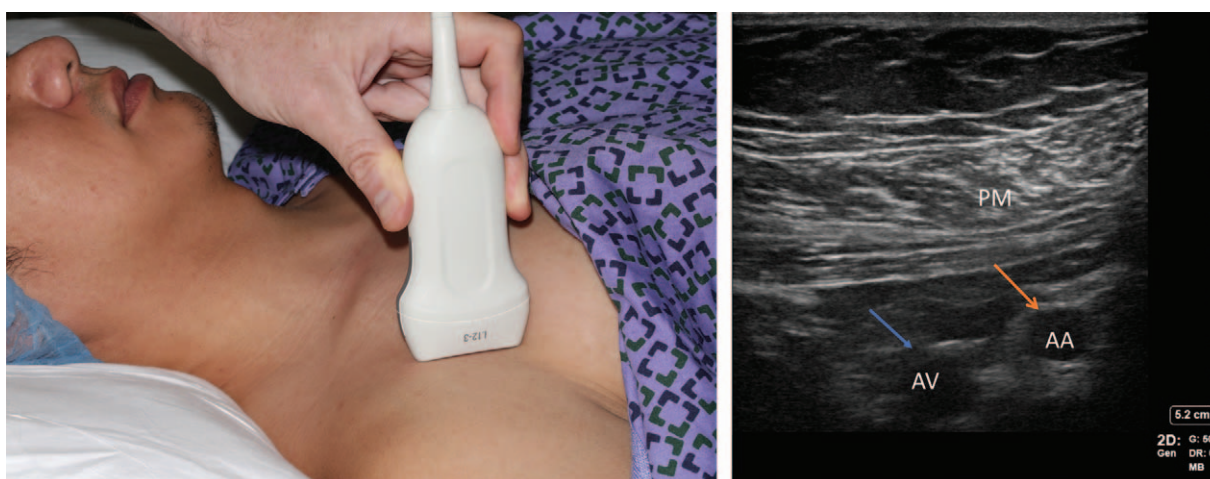### Overall complications

The reported rate of complications and malposition in the study by Xu *et al.*<sup>50</sup> was lower when ultrasound guidance was used: 0.6 vs. 3.7% ( $P=0.001$ ) and 0.6 vs. 2.1% ( $P=0.017$ ), respectively. The study by Liccardo *et al.*<sup>51</sup> did not report major complications such as pneumothorax but supported ultrasound guidance because it was associated with a lower risk of malposition of the pacemaker leads.

### First-attempt success

The study by Xu *et al.*<sup>50</sup> found that ultrasound guidance was associated with a first-attempt success rate of 96% compared with 81.7% using landmarks. Liccardo *et al.*,<sup>51</sup> in a smaller RCT using ultrasound guidance to cannulate the axillary vein for pacemaker wire implantation, reported that the frequency of success at the first attempt

Fig. 3



Short axis view of the right axillary vein in an adult patient. External view: the ultrasound probe is placed under the clavicle, perpendicular to its main axis. Ultrasonographic image: the blue arrow indicates the axillary vein (AV); the red arrow indicates the axillary artery (AA); PM, pectoralis muscle.

was comparable to that of subclavian vein cannulation using a landmark technique (93.3 vs. 95.6%). They concluded that their ultrasound-guided approach to the axillary vein was as effective and as well tolerated as the classical technique for subclavian vein cannulation, and with the added advantage of being free from the risk of pneumothorax or damage to the pacemaker wires.

There were no data in either of the studies regarding the time required to puncture or to cannulate the axillary vein.

### Recommendations

- (1) The quality of evidence on which to base recommendations is generally weak, with data from only a few, small, clinically heterogeneous RCTs.
- (2) We recommend the use of ultrasound guidance during axillary vein cannulation, as it reduces the risk of major complications and increases the rate of first-time success when compared with the landmark technique (2A).

### Should ultrasound guidance be used during cannulation of the femoral vein, or other veins in the groin, for venous line placement in adults?

There is a huge body of evidence-based literature proving that ultrasound guidance significantly reduces early mechanical complications, late infectious and thrombotic complications, the number of attempts and the costs of femoral-inserted catheters. The veins in the groin, such as the femoral vein, are usually punctured when the supraclavicular or infraclavicular areas cannot be accessed (e.g. skin lesions or infections, burns, trauma and so on), when the superior vena cava cannot be cannulated (e.g. superior vena cava syndrome due to a mediastinal mass, surgical corrections of congenital heart diseases, superior

vena cava occlusion and thrombosis and so on) or as a second option after the right IJV when a dialysis catheter is needed. Figure 4 shows a transverse view of the femoral vein.

A recent Cochrane meta-analysis concluded that ultrasound-guided cannulation of the femoral vein provides only small benefit when compared with the landmark technique.<sup>15</sup> The analysis included data from only four controlled trials (randomised or not). Although there are fewer randomised clinical trials of ultrasound-guided femoral vein cannulation than IJV cannulation, there is a broad consensus that the benefits of ultrasound guidance can be extended to all venous access sites.<sup>15–17</sup> This panel of experts, after systematic update and review of recent evidence, concurs with this opinion: we concluded that the lack of benefit is more likely related to a lack of adequate studies rather than to a failure of ultrasound at these sites.

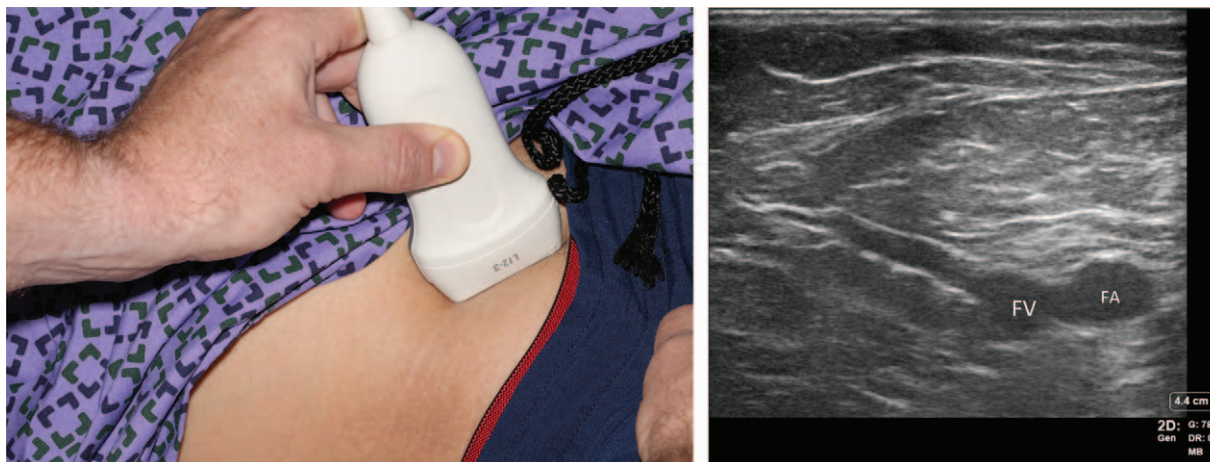
The use of ultrasound guidance gives the further option of using the superficial femoral vein at the mid-thigh level. This technique enables a catheter exit site in a clean, flat and stable area where dressings can be managed optimally, reducing the risk of infections and thrombosis, and without the need for tunnelling the catheter.

We screened 218 abstracts for relevance and 15 papers were selected for analysis: only 10 of these were finally included to inform the current guidelines. We analysed the advantages/disadvantages of ultrasound guidance when compared with landmark or other techniques for insertion of femoral catheters.

### Overall success

Our meta-analysis on four prospective observational studies<sup>555</sup> and two RCTs<sup>15,56</sup> showed that ultrasound guidance is

Fig. 4



Short axis view of the femoral vein in an adult patient. External view: the ultrasound probe is placed at the groin. Ultrasonographic view: FV, femoral vein; FA, femoral artery.

more effective than landmark and other techniques, RR 0.2 (95% CI, 0.12 to 0.34), equivalent to 160 more successful cannulations per 1000 procedures (95% CI, 116 to 176).

### Major complications

Ultrasound guidance reduces the incidence of major complications such as arterial puncture, posterior wall puncture, haematomas and infections. Haematomas, although sometimes considered to be minor complications, are not harmless, as they are precursors of infection and thrombosis. We performed a random effects meta-analysis on eight prospective observational studies<sup>52–55,57–59</sup>; this revealed that USG was associated with fewer complications than landmark or other techniques with a RR (95% CI) of 0.4 (0.30 to 0.55),  $I^2 = 29%$ : equivalent to 121 fewer complications per 1000 procedures (95% CI, 91 to 142). A separate analysis of two RCTs<sup>19,56</sup> showed that ultrasound guidance provides a significant reduction in overall complications compared with landmark or other techniques with a RR (95 CI) of 0.4 (0.3 to 0.55),  $I^2 = 0$ .

### Number of attempts

In one RCT<sup>56</sup> and in two prospective observational studies,<sup>52,58</sup> the total number of attempts was significantly lower with ultrasound guidance than with any other technique: reducing the number of attempts may indirectly reduce the rate of infections.

### Time to successful cannulation

Only one RCT<sup>19</sup> and two prospective observational studies<sup>52,58</sup> considered the time to cannulation as a primary or secondary outcome. A meta-analysis showed that ultrasound-guided cannulation is faster (90 s vs. 5 min) than any other technique. By reducing the time to successful cannulation, ultrasound-guided cannulation may indirectly reduce infectious complications related to the puncture technique, by reducing the chance of accidental breakdowns of the sterile technique.

### Recommendations

- (1) The quality of evidence on which to base recommendations is weak, with data from only small RCTs and cohort studies with high heterogeneity and some methodological problems.
- (2) We recommend the use of ultrasound guidance for cannulation of the femoral vein (or other veins in the groin) in adults, as it is safer, it reduces the incidence of major complications, it improves the success rate and it reduces the time to successful cannulation (1C).
- (3) We also recommend the use of ultrasound guidance for cannulation of the femoral vein (or other veins in the groin) in adults, as it may indirectly decrease infectious and thrombotic complications by reducing the likelihood of some risk factors (e.g. haematoma) related to the puncture (1C).

- (4) We suggest considering ultrasound-guided puncture of the superficial femoral vein at the mid-thigh to enable an exit site in a safe area, reducing the risk of infection and thrombosis (2C).
- (5) We recommend an out-of-plane puncture of the femoral vein using a short axis view. A short axis view allows a panoramic view of arteries and nerves and so helps to avoid inadvertent damage to these structures (1C).

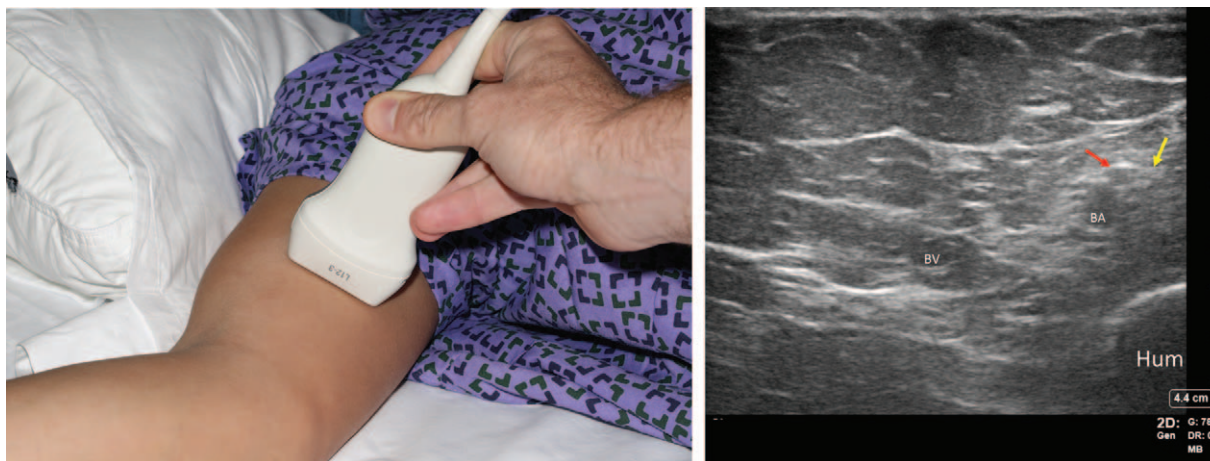
### Should ultrasound guidance be used for cannulation of any peripheral vein in adults during elective or emergency procedures?

Peripheral vein puncture and cannulation is a routine and very common procedure required in a broad range of clinical applications, from peripheral venous catheters (short and long cannulas, midlines and so on) to peripherally inserted central venous catheters (PICCs). A peripheral venous catheter is often needed to maintain fluid and electrolyte balance, deliver blood products and administer drugs, either in emergency or elective situations. For short, and medium-term inpatient and outpatient care, a PICC may be needed for the purpose of frequent blood sampling, for administration of drugs with low (<5) or high (>9) pH, for infusion of solutions with high osmolality (>500 mOsm l<sup>-1</sup>) and/or for administration of parenteral nutrition with high osmolality (>800 mOsm l<sup>-1</sup>)<sup>60</sup> or even for haemodynamic monitoring.<sup>61</sup> Figure 5 shows a transverse view of the veins in the mid upper arm level.

The traditional cannulation technique for peripheral intravenous catheters based on visual inspection and palpation of superficial peripheral veins of the arm can often be difficult for many reasons: small peripheral veins, subcutaneous fat, previous repeated attempts at cannulations, chronic medications or drug abuse, age-related diseases, malnutrition or dehydration.<sup>62</sup> Difficult peripheral venous access, defined as the absence of veins easily visible or palpable in both arms after tourniquet placement, is associated with repeated unsuccessful attempts, delay in management, increase in costs, adverse events such as nerve damage, paraesthesia, haematoma, arterial puncture and placement of unnecessary centrally inserted central venous catheters.<sup>63,64</sup> Many authors have investigated the factors associated with difficult peripheral venous access, and different scores (so-called 'DIVA' scores) have been validated in adult and paediatric settings.<sup>62,65</sup> USG provides a promising strategy for obtaining peripheral intravenous access in patients with predicted difficult venous access. When cannulating superficial peripheral veins, it is important to consider some characteristics of the vessel and of the vascular access device that may impact on a procedure's chance of success and catheter survival: in particular the depth of the vein and the length of the device.<sup>60,66</sup> Although ultrasound guidance is suitable for veins at a depth of



Fig. 5



Short axis view of the deep vein of the arm in an adult patient. External view: the ultrasound probe is placed over the anterior aspect of the arm. Ultrasonographic image: Hum, humerus; BV, basilic vein; BA, brachial artery; the red arrow indicates the small brachial vein; the yellow arrow indicates the brachial nerve.

more than 7 to 8 mm, more superficial veins (depth <7 mm) are not easily visualised and punctured, as they are compressed by the probe itself and by the pressure transmitted by the needle from the skin to the soft tissues. Furthermore, the vein depth is an important factor when choosing the length of catheter.<sup>60</sup> Longer catheters (i.e. mini-midlines, which are 8 to 15 cm long) have longer survival than short peripheral cannulas.<sup>66,67</sup> Keyes *et al.*<sup>67</sup> also showed that for vessels greater than 1.2 cm in depth or for insertion into the deep brachial or basilic veins of the arm, the survival probability at 48 h of traditional short peripheral cannulas was significantly lower than placement into more superficial vessels.

PICCs must be placed by puncturing a deep peripheral vein of the arm above the elbow crease, thus increasing success rate and reducing thrombotic and infectious complications. The puncture of these veins requires the use of ultrasound guidance.<sup>12,14</sup> It is widely accepted that PICCs should be routinely inserted at mid-arm level by ultrasound guidance and using micro-introducer technique.<sup>12</sup>

We screened 3911 articles for relevance and 108 papers were selected for analysis: only 15 of these were finally included to inform the guidelines. We analysed the outcomes of ultrasound-guided cannulation of peripheral veins vs. any other technique in adults, for both elective and emergency procedures.

#### Overall success

Our random effects meta-analysis of four RCTs indicated that ultrasound-guided cannulation compared with landmark is more effective with RR of 0.43 (95% CI, 0.24 to 0.80), equivalent to 338 (95% CI, 129 to 481) more successful cannulations per 1000 procedures, but there

was a high level of heterogeneity ( $I^2 = 85\%$ ).<sup>64,68–70</sup> A further analysis on five prospective observational studies found that ultrasound-guided cannulation is better than landmarks with RR of 0.21 (95% CI, 0.08 to 0.55), equivalent to 220 (95% CI, 146 to 248) more successful cannulations per 1000 procedures, but again there was a high level of heterogeneity ( $I^2 = 77\%$ ). In addition to fewer skin punctures, we found increased patient satisfaction associated with the use of ultrasound guidance for peripheral vein cannulation.<sup>71–75</sup> This might be associated with a reduced number of attempts in patients with difficult peripheral venous access.

#### Overall complications

The most common complications reported were haematoma and arterial punctures. Other complications included nerve injury with pain and transient neurological deficit, and nerve injury with transient nerve pain but no associated neurological deficit. Specifically, for PICC placement, the most common complications were venous thrombosis, bleeding, tip malposition and arm discomfort. Our random effects meta-analysis of five prospective observational studies<sup>71,73–76</sup> revealed that ultrasound-guided cannulation compared with landmark or any other technique was associated with RR (95% CI) of 0.32 [0.19 to 0.54,  $I^2 = 34\%$ , equivalent to 222 (95% CI, 180 to 252) fewer complications per 1000 procedures. Only one RCT<sup>70</sup> was found and, in this, the overall complications were among the secondary outcomes. In this study, the authors enrolled 1189 individuals, the majority of the total number of patients included in our analysis. They found that ultrasound guidance was superior to landmarks or any other technique for those cases with moderately difficult or difficult intravenous access. But these authors also found that the landmark technique was more

successful in patients with easy venous access, or if it was a second attempt after a previous failure.

#### **Time to successful cannulation**

In three prospective observational studies, the high level of heterogeneity ( $I^2 = 100\%$ ) precludes reporting our meta-analysis.<sup>71,72,77</sup> One of these studies reported ultrasound guidance to be two times faster than the landmark technique (mean 26.8 vs. 74.8 min).<sup>71</sup>

Our meta-analysis of six RCTs showed no difference in time to cannulation using ultrasound-guided cannulation vs. landmarks. Evaluation of individual studies suggests that when an expert operator can easily see or palpate the vein, landmarks seem to be superior especially in terms of procedural duration. In contrast, ultrasound guidance is more successful when a superficial vein is not clearly visible or palpable and the access is difficult.<sup>63,64,70,78–80</sup>

#### **Recommendations**

- (1) The quality of evidence on which to base recommendations is weak, with data from only small RCTs and prospective cohort studies with high heterogeneity.
- (2) We recommend adopting and applying a tool for the assessment of difficult peripheral venous access in order to best identify those patients who may benefit from ultrasound-guided peripheral vein cannulation **(1C)**.
- (3) We recommend the use of ultrasound guidance for peripheral vein cannulation in adults with moderate to difficult venous access, both in emergency and elective situations, as it is safer and more effective in terms of reduction of complications and improved overall success rate and reduced time to achieve vascular access **(1C)**.
- (4) We recommend the use of ultrasound before peripheral vein cannulation in order to evaluate the location of the vein as well as its diameter and depth. This will enable the choice of the most appropriate length and diameter of peripheral vascular access device and the safest puncture site, so as to reduce risks of accidental dislodgment and extravasation, phlebitis and thrombus formation **(1C)**.
- (5) We recommend routine use of ultrasound for peripherally inserted central catheter placement, taking care that the exit site is located at mid-arm level **(1C)**.

#### **Should ultrasound guidance be used for cannulation of any central vein for long-term vascular access device placement in adults?**

A long-term central venous catheter is a device implanted so as to obtain long-term stabilisation and to protect it against extraluminal contamination.

This definition includes the following long-term central venous devices:

- (1) A totally implanted central venous catheters in which the catheter is connected to a subcutaneous reservoir (Port catheters);
- (2) A central venous catheter tunneled and cuffed;
- (3) A central venous catheter tunneled, not cuffed but stabilised with a subcutaneously anchored system.

There are some complications that are specific to this type of catheter where evidence suggests ultrasound may play an important role in prevention and diagnosis. We screened for 122 abstracts for relevance and 99 papers were selected for analysis, but only four of them<sup>36,81–83</sup> were finally included to inform the current guidelines.

We analysed the use of ultrasound guidance compared with landmark or other techniques in terms of the rate of pinch-off and infectious and thrombotic complications when placing long-term central venous access devices.

#### **Catheter-related thrombosis**

By reducing the number of puncture attempts and thus the endothelial damage, and by decreasing technical failure rates and likelihood of hematoma formation, which can cause vein collapse, ultrasound guidance indirectly reduces the incidence of catheter-related thrombosis compared with landmark guidance or surgical placement.<sup>12,81,83,84</sup> Furthermore, ultrasound enables early diagnosis of catheter-related thrombosis and its differentiation from a fibroblastic sleeve.

#### **Catheter-related infections**

By reducing the number of puncture attempts and the subsequent risk of haematoma formation, which represents an ideal environment for bacterial replication, and decreasing the time to achieve a successful cannulation and the subsequent possible breakdown of the sterile technique, ultrasound indirectly reduces the incidence of catheter-related infections, in both adults and children, when compared with landmark guidance or surgical placement.<sup>12,81,83,84</sup>

#### **Pinch-off syndrome**

Pinch-off consists of damage to a catheter (especially if made of silicone) in its extravascular tract due to compression between the first rib and clavicle before it enters the subclavian vein. Compared with the 1.7% rate of pinch-off syndrome with the landmark technique, there were no cases in the ultrasound group.<sup>82</sup> This is because the catheter, as shown by computed tomography (CT) scan,<sup>82</sup> enters the vessel before it passes between the first rib and the clavicle.

#### **Cost-effectiveness**

Biffi *et al.*<sup>83</sup> demonstrated that ultrasound guidance for long-term central venous catheter placement is cost-effective, with an estimated saving of €2000 per patient when compared with landmark guidance or surgical placement.

### Recommendations

- (1) The quality of evidence on which to base recommendations is weak, with data from only small RCTs with high heterogeneity.
- (2) We recommend ultrasound guidance for placement of long-term vascular access devices, as it has been shown to significantly reduce early mechanical complications (arterial puncture, hematoma, pneumothorax, haemothorax) **(1C)**.
- (3) We recommend ultrasound guidance for placement of long-term vascular access devices, as it has been shown to be cost-effective by indirectly reducing complications such as catheter-related thrombosis and catheter-related infections **(1C)**.
- (4) We recommend ultrasound-guided puncture of the axillary vein at the thorax for long-term vascular access device placement, as it has been shown to reduce the risk of pinch-off syndrome **(1C)**.
- (5) We recommend ultrasound for catheter tip location and tip navigation to avoid primary malposition **(1C)**.
- (6) We recommend preprocedural sonographic evaluation of all possible venous options for long-term vascular access device placement to plan and choose the safest approach **(1C)**.
- (7) We recommend ultrasound for timely diagnosis of all potentially life-threatening complications (pneumothorax, haemothorax, cardiac tamponade and so on) after central venepuncture, as it has been shown to be more accurate and faster than a chest radiograph **(1B)**.

### Should ultrasound guidance be used for cannulation of any artery in adults during elective procedures?

Arterial catheter placement is a common procedure performed in a broad range of clinical settings (e.g. medical emergencies, major elective and emergency surgery, ICU) mainly for haemodynamic monitoring and repeated arterial blood sampling.<sup>86</sup> The sites most commonly used for arterial cannulation are the radial and femoral arteries. The radial artery is the preferred site for arterial cannulation because of its consistent anatomical accessibility, ease of cannulation, low rate of complications and ease of optimal nursing and wound dressing.<sup>86</sup> Failing the radial artery, the femoral artery is the next choice.<sup>86</sup> Although one advantage of femoral artery cannulation is that the vessel is larger than the radial artery, it is associated with a higher risk of infection.<sup>86,87</sup>

The traditional technique for arterial catheter placement is the pulse palpation method in which the pulse of the artery is the landmark for the puncture site and needle direction. However, accurate localisation of small arteries using the pulse palpation method is technically difficult and can be very challenging particularly in the presence of dehydration, hypotension or haemodynamic instability, and in those patients with vascular diseases. In all these cases, multiple cannulation attempts are common and may result in serious complications. The most

frequent complications are arterial occlusion, haematoma formation and nerve injury. Although rare, other serious complications, such as permanent ischaemic damage, sepsis and pseudo-aneurysm formation, may occur. The use of ultrasound guidance has been proposed to minimise these complications.

Before radial artery cannulation is attempted, Allen's test is commonly used to assess collateral circulation of the hand through the ulnar artery. Recently, a modified Allen's test performed using duplex colour-Doppler imaging and pulsed Doppler has been proposed.<sup>88,89</sup> These studies have shown that dynamic duplex ultrasonography and Doppler can provide more accurate anatomical and physiological information about the ulnar collateral blood flow than the traditional Allen's test. In fact, the absence of reverse flow in the superficial palmar branch in the hand upon radial artery occlusion or an absence of flow in the dorsal digital artery to the thumb during radial artery compression appear to represent contraindications to radial artery catheterisation.<sup>89</sup>

Sixty-six articles were screened for relevance. Twenty-five papers were selected for analysis, 13 of which were included to inform the guidelines for radial artery catheterisation, but with only three included for femoral artery cannulation. We analysed the outcomes of ultrasound guidance for placement of arterial catheters vs. any other technique of arterial cannulation in adults, in both elective and emergency procedures.

### Overall success

Using the pulse palpation technique, a failure to obtain arterial access has been reported in up to 20% of radial artery catheterisations and 13.6% of femoral artery catheterisations.

Our random effects meta-analysis of 10 RCTs<sup>90–99</sup> of radial artery cannulation showed that ultrasound guidance was more effective than pulse palpation or any other technique with a RR (95% CI) of 0.42 (0.26 to 0.68,  $I^2=30\%$ ), equivalent to 39 (95% CI, 10 to 51) more successful cannulations per 1000 procedures

Two randomised controlled trials<sup>100,101</sup> of femoral artery catheterisation showed that ultrasound guidance increases success rate when compared with pulse palpation technique with RR 0.74 (95% CI 0.55 to 0.99), equivalent to 73 more successful attempts per 1000 procedures.

### Overall complications

Our random effects meta-analysis of eight RCTs<sup>90,95–98,102–104</sup> of radial artery catheterisation showed that ultrasound-guided technique compared with any other technique is associated with 67 (95% CI, 37 to 89) fewer complications per 1000 procedures with a RR of 0.56 (95% CI, 0.30 to 1.03),  $I^2=70\%$ . We made a further random effects meta-analysis of three RCTs<sup>100,101,105</sup>

of femoral artery cannulation that revealed that ultrasound guidance compared with any other technique was associated with 41 fewer complications per 1000 procedures with a RR of 0.36 (95% CI, 0.16 to 0.82);  $I^2 = 41\%$ .

#### First-time successful cannulation

Our random effects meta-analysis of 11 RCTs<sup>91–95,98,99,102–104</sup> of radial artery catheterisation showed that ultrasound-guided cannulation compared with any other technique is more effective in increasing success rate at the first attempt with 187 (95% CI, 103 to 285) more successful first-time cannulations per 1000 procedures with a RR of 0.66 (95% CI, 0.60 to 0.72);  $I^2 = 47\%$ . Two RCTs of femoral artery catheterization (100, 101) found that ultrasound guidance compared with any other techniques allows a significantly increased first-time success rate with a RR of 0.31 (95% CI 0.26 to 0.38), equivalent to 341 more successful first-time cannulations per 1000 procedures (95% CI 3.02 to 3.72).

#### Time to successful cannulation

A meta-analysis of 10 RCTs<sup>90,91,93,94,96–99,102,104</sup> showed that ultrasound-guided catheterisation of the radial artery was 29 (95% CI, 25 to 84) s faster than the pulse palpation or any other technique. Two RCTs<sup>100,101</sup> of femoral artery catheterisation found that ultrasound guidance was 25 (95% CI 14 to 37) s faster than other techniques. Although the time saved may not be relevant in clinical practice, these data indicate that ultrasound guidance does not waste time, which is relevant in the emergency situation.

#### Short axis out-of-plane vs. long axis in-plane for radial artery cannulation

Two different approaches for ultrasound-guided radial artery cannulation can be used: short-axis + out-of-plane and long-axis + in-plane techniques. Moreover, some authors have proposed an oblique approach<sup>106</sup> and new articles are currently in publication regarding this new approach.

The current available literature is equivocal in reporting the superiority of the short-axis out-of-plane technique over the long-axis in-plane technique for radial artery cannulation in both adults and children. Berk *et al.*<sup>107</sup> showed that rate of cannula insertion success at the first attempt was 51 and 76% with the use of short-axis out-of-plane or long-axis in-plane, respectively. Also, Stone *et al.*,<sup>108</sup> in a simulated model, found that the long-axis + in-plane technique was associated with improved visibility of the needle tip during puncture, which may help to decrease the risk of complications. On the contrary, Quan *et al.*<sup>109</sup> showed that the first-attempt success rate was significantly higher in a slightly modified short-axis + out-of-plane technique than the long-axis + in-plane technique. Although Song *et al.*<sup>110</sup> have recently found a similar success rates with either technique in

paediatric patients, the rate of posterior wall puncture was lower with the long-axis + in-plane technique. Finally, Sethi *et al.*<sup>111</sup> showed that short-axis + out-of-plane and long-axis + in-plane for radial artery cannulation are similar in terms of overall success and time to successful cannulation in adult patients.

#### Recommendations

- (1) The quality of evidence on which to base recommendations is generally weak, with relatively few RCTs that have a high degree of heterogeneity.
- (2) We recommend the use of ultrasound guidance for radial artery catheterisation in all adult hypotensive, hypovolaemic or haemodynamically unstable patients, and in those with vascular disease and in small arteries with a weak and/or thin pulse, as it has been proved to be more effective in reducing complications, time to cannulation and number of attempts, and in increasing overall success and first-time success rates **(1B)**.
- (3) We recommend the use of ultrasound guidance in all adults needing femoral artery catheterisation, as it has been shown to be safer in reducing major and minor complications, with increased overall success and first-time success rates, and, thus, reduced time to cannulation **(1B)**.
- (4) 'Use of a short axis view out-of-plane approach is not superior to a long-axis view in-plane approach when ultrasound guidance is used for radial artery catheterisation **(2A)**.
- (5) Before radial artery catheterisation, we suggest a modified Allen's test is performed using duplex ultrasonography and colour-Doppler to evaluate ulnar artery collateral blood flow: absence of reverse flow in the superficial palmar branch in the hand during radial artery compression or absence of flow in the dorsal digital artery to the thumb during radial artery compression represent contraindications to radial artery catheterisation **(2C)**.
- (6) The catheterisation of a small radial artery is not recommended, as it is associated with the development of a clinically relevant pressure gradient (central to radial) during cardiac surgery. Thus, values obtained by invasive blood pressure measurement in a small radial artery can be falsely low<sup>112</sup> **(2C)**.

#### Should ultrasound be used for confirmation of the correct position of the central venous catheter tip for any patient and any elective or emergency situation?

Prevention of central venous catheter tip malposition is of paramount importance, as it has been associated with significant complications, including central venous or superior vena cava thrombosis, arrhythmias, cardiac tamponade and haemodynamic monitoring inaccuracy. Moreover, with malposition, appropriate treatment may be delayed with subsequent further related

complications. In this regard, the intracavitary electrocardiographic (IC-ECG) method<sup>60,85,113,114</sup> is currently recommended in international guidelines<sup>84</sup> as accurate, well tolerated and cost-effective for assessing the proper location of the central venous catheter tip. However, this method is commonly considered to be applicable only when there is a well defined and identifiable P wave in the ECG trace. Although a few studies have recently suggested that IC-ECG might also be used in patients with atrial fibrillation after some appropriate modifications of the basic technique, in patients with a pacemaker or with other arrhythmias, IC-ECG is still considered to be not applicable. As bedside chest radiograph has been shown to be inaccurate in identifying the catheter tip location due to the inaccuracy of the radiological landmark for the cavo-atrial junction, ultrasound imaging has been proposed as an alternative technique to IC-ECG and chest radiograph for tip location. Indeed, the application of ultrasound to vascular access should not be limited to venepuncture but should be extended to assist in all steps of the procedure.<sup>11,115</sup> Specifically, in regard to the prevention of primary malposition, ultrasound may play two roles as a 'tip location' and a 'tip navigation' technique.<sup>121</sup> Ultrasound-based tip navigation techniques can be used to confirm that the catheter or the guidewire is threading towards the cavo-atrial junction by sonographic visualisation throughout the ipsilateral brachiocephalic vein, ruling out catheter misdirection into the ipsilateral IJV or other superior vena cava tributary veins (e.g. the contralateral brachiocephalic vein). Sonographic tip navigation may be performed with the same linear probe used for the puncture.

As a tip location technique, ultrasound allows direct or indirect visualisation of the catheter tip or the J-guide-wire at the cavo-atrial junction, upper right atrium or in the lower superior vena cava by means of transthoracic echocardiography.<sup>118–149</sup> Different approaches and different protocols have been described in the literature on this topic. Four different echocardiographic views have been tested: the apical four-chamber view, the subcostal four chambers view, the subcostal bi-caval view and the suprasternal/supraclavicular view. Both of the four chambers views allow only evaluation of the right atrium without visualisation of the superior vena cava or inferior vena cava. On the contrary, the subcostal bi-caval view, the most studied approach, allows visualisation of the superior vena cava, cavo-atrial junction, right atrium and inferior vena cava. Four groups of researchers<sup>116–119</sup> have studied the suprasternal/supraclavicular view, which allows identification of the confluence between the two brachiocephalic veins, the superior vena cava, the right branch of the pulmonary artery and the aortic arch. These structures enable indirect identification of the cavo-atrial junction.

Ultrasound-based tip navigation may be used during the procedure to help the operator in directing the guidewire

and/or the catheter in the right direction. On the contrary, tip location methods verify that the tip of the catheter is in the desired definitive position. Thus, it is clear that tip navigation does not replace the tip location method, and ideally both should be integrated.

We screened 976 titles and abstracts for relevance and 35 of these were assessed for eligibility and selected for analysis: only 32 of these<sup>118–149</sup> were finally included to inform the current guideline. The included studies used different ultrasound protocols and reported a wide range of diagnostic accuracy. To address this issue, we performed a meta-analysis of these studies. We analysed feasibility and diagnostic accuracy of ultrasound-based tip navigation and tip location techniques as well as the time required to perform them.

#### **Accuracy and feasibility**

Ultrasound for tip location was feasible in 93% of cases (2725 catheters out of a total of 2933 patients enrolled across all the included studies). The reasons for this reported 7% of failure rate were the poor echogenicity and high acoustic impedance of the chest restricting the use of all subcostal, suprasternal/supraclavicular and apical views; other factors such as obesity, recent open abdominal surgery, overinflation of the stomach or colon, presence of a drainage tube and so on may restrict the use of the subcostal acoustic window.

Overall accuracy of the ultrasound protocols was 97.3 vs. 96.7% with chest radiograph.

We performed a meta-analysis of 31 prospective observational studies and one RCT. Different sonographic methods have been assessed in the included studies. The ultrasound protocols can be classified into four groups: vascular ultrasound and transthoracic echocardiography; transthoracic echocardiography combined with contrast-enhanced ultrasound; a combination of first and second; and, supraclavicular ultrasound. Contrast-enhanced ultrasound is defined as a flush of the central venous catheter with agitated or non-agitated 0.9% saline, generating microbubbles visible during transthoracic echocardiography. In 11 of these studies,<sup>118,120,121,125,130,131,132,136,145,150,152</sup> vascular ultrasound was coupled with transthoracic echocardiography with or without contrast-enhanced ultrasound, whilst in 22 studies<sup>119,120,124–127,128,130,131–138,145–150</sup> catheters were visualised by ultrasound directly after placement. Interestingly, in six studies,<sup>129,116,117,118,151,152</sup> the advancement of the guidewire was assessed in real-time by ultrasound, showing that this technique can significantly reduce the incidence of malposition.

The group of studies in which transthoracic echocardiography with or without contrast-enhanced ultrasound was tested produced a pooled sensitivity of 75% (95% CI, 72.5 to 77.3) and a pooled specificity of 99.3% (95% CI, 96.6 to 99.6). In these studies, after central venous catheter

placement, an apical four-chamber view or, more usually, a subcostal bi-caval view was obtained. The central venous line was flushed with either 10 or 20 ml of 0.9% saline solution vigorously shaken, with or without 1 ml of air, to create microbubbles. If the central venous catheter was positioned correctly, the microbubbles were visible on transthoracic echocardiography within 2 s in the majority of publications (within 0.5 s for Meggiolaro *et al.*<sup>120</sup>): a delay more than 2 s indicated incorrect placement of the catheter tip.

When transthoracic echocardiography with contrast-enhanced ultrasound was coupled with vascular ultrasound for catheter tip navigation to ensure the correct placement of the central venous catheter, this yielded the highest sensitivity of 82.6% (95% CI, 79.1 to 85.7) with a specificity of 99% (95% CI, 97.9 to 99.7). After central venous line insertion, the right atrium and superior vena cava were evaluated through the subcostal bi-caval view. If the catheter tip could not be visualised at the cavoatrial junction or in the lower superior vena cava through this method, all ipsilateral and contralateral superior vena cava tributary veins were scanned to detect tip malposition.

When transthoracic echocardiography with contrast-enhanced ultrasound was coupled with vascular ultrasound, the specificity remained high 99.2% (95% CI, 97.9 to 99.7), while the sensitivity dropped again to 50% (95% CI, 45.7 to 54.3).

The supraclavicular ultrasound imaging group produced a specificity of 91.8% (95% CI, 83.2 to 96.3), but due to absent cases of malposition, the sensitivity could not be calculated. In these studies, the authors used a microconvex ultrasound transducer placed in the right supraclavicular fossa. After having obtained an appropriate view of the superior vena cava close to the right branch of the pulmonary artery, the guidewire was inserted under real-time ultrasound guidance and the central venous catheter advanced along the guidewire. When an adequate view of the right branch of the pulmonary artery and the lower superior vena cava is not obtained, this technique may be considered a tip navigation technique.

We also conducted a subgroup analysis of three prospective observational studies of paediatric patients.<sup>121–123</sup> In these studies, different echocardiographic approaches were used, yielding a sensitivity of 83.3% (95% CI, 78.1 to 87.5) with 100% specificity (95% CI, 98.2 to 100).

The prevalence of central venous catheter malposition in the total population of patients included in our meta-analysis was 6%. This may be the main reason for the low sensitivity reported: small changes in the number of false negatives will significantly influence the sensitivity. Further reasons for the wide variability in specificity and sensitivity may be attributable to the use of different

sonographic approaches and protocols and lack of standardisation of the operators' training. Moreover, the choice of chest radiograph as the reference standard is inappropriate, as it is known to be inaccurate for tip location.<sup>85,114</sup>

#### **Time to diagnosis**

Our meta-analysis of 17 prospective observational studies and one RCT showed that ultrasound enabled a bedside diagnosis of malposition 80 min (95% CI, 62 to 98 min) faster than performance and interpretation of a chest radiograph.<sup>117–121,124–136</sup>

#### **Cost-effectiveness**

We found only one observational prospective cohort study<sup>133</sup> of cost-effectiveness. In this study, the authors performed a cost-effectiveness analysis of vascular ultrasound along with transthoracic echocardiography with contrast-enhanced ultrasound for tip location coupled with lung ultrasound to rule out pulmonary complications. The results indicated a saving of €2.81 per procedure compared with chest radiograph.

#### **Recommendations**

- (1) The quality of evidence on which to base recommendations is generally weak, with relatively small RCTs and prospective cohort studies that have a high degree of heterogeneity.
- (2) When an intracardiac electrocardiogram is not applicable, we recommend using real-time ultrasound to detect and prevent central venous catheter malposition, as it has been shown to be well tolerated, feasible, quickly performed and interpreted at bedside, and more accurate and faster than a chest radiograph **(1C)**.
- (3) We recommend combining vascular ultrasound for guidewire and central venous line tip navigation with transthoracic echocardiography for tip location **(1C)**.

#### **Should ultrasound be used for verification of immediate postprocedural life-threatening complications after central venous catheterisation?**

As mentioned above in this guideline, today, the modern application of ultrasound in the field of vascular access should be extended more globally to assist in all steps of the procedure, including diagnosis or exclusion of both early and late complications.<sup>115</sup>

Several studies have been published about the usefulness and effectiveness of PLUS for the early diagnosis of pleural-pulmonary complications after central venous catheter placement when the pleura could have been damaged.<sup>122,132,133,137,138</sup> Even if performed by ultrasound guidance, difficult cases of central venous line placement may have a small risk of pulmonary complications, especially when puncturing the subclavian vein in the supraclavicular area, in the transitional region

between the subclavian vein and the brachiocephalic vein or when accessing the axillary vein at the thorax. The inadvertent damage of the pleura during central venepuncture can not only result in an obvious pneumothorax, but also sometimes a small so-called 'radio-occult' pneumothorax occurs that is usually missed by chest radiograph.<sup>139–141</sup> PLUS has been shown to be more sensitive than supine chest radiograph and similar to a computed-tomography scan in the detection of a post-interventional or posttraumatic small occult pneumothorax.<sup>142,143</sup> Even if drainage of a small occult pneumothorax in a stable patient is not indicated, follow-up observation, and sonographic monitoring is important, as in some cases the pneumothorax may progress quickly to cause haemodynamic instability. Ultrasound has also been shown to be a useful tool for the diagnosis and monitoring of late complications such as catheter-related thrombosis.<sup>144</sup>

We screened 1523 titles and abstracts for relevance; 16 were assessed for eligibility and selected for analysis, but only 14 of them<sup>118,120,122,126,128,130–134,136–138,145</sup> were used to inform the current guideline.

#### **Accuracy and feasibility**

In the included studies, PLUS was the main sonographic diagnostic procedure performed to exclude pleural-pulmonary complications after central venepuncture. The prevalence of pleural-pulmonary complications among the population of patients enrolled in the studies included in our meta-analysis was low (0.94%).

Our meta-analysis showed that PLUS was feasible in 100% of cases. The overall accuracy of PLUS in ruling-out or detecting pleural-pulmonary complications was 100%. From a total of 1382 central venous catheterisations, 13 pneumothoraces occurred. PLUS correctly diagnosed all 13, while three were missed with chest radiograph. Overall pooled specificity of PLUS for diagnosis of pneumothorax was 100% (95% CI, 99.7 to 100).

As ultrasound guidance significantly reduces the rate of pleura-pulmonary complications, in nine studies<sup>118,120,128,130,132,134,137,138,145</sup> out of 14 the sensitivity was not estimable, as none occurred. In the remaining 5 studies,<sup>122,126,131,133,136</sup> the pooled sensitivity of PLUS for pneumothorax diagnosis was 100% (95% CI, 99.7 to 100) compared with a pooled sensitivity for chest radiograph of 77% (95% CI, 75 to 79).

We found one prospective observational case–control cohort study with an historical control group,<sup>144</sup> proving that ultrasound is an effective and valid tool for diagnosis and follow-up of treatment for catheter-related thrombosis and catheter-related infectious thrombosis. The authors of this study found that ultrasound allowed early diagnosis of such complications and enabled their prompt and timely treatment, with significant positive effects on outcomes. Compared with the historical control group

(ranging from 1 to 6 years before enrolment of the prospective cohort), patient survival was found to be increased in the modern ultrasound group (95 vs. 80%).

#### **Time to diagnosis**

Our meta-analysis of 11 prospective studies<sup>118,120,126,128,130–134,136,145</sup> found that ultrasound allows a quicker diagnosis at the bedside of all possible life-threatening respiratory complications related to central venepuncture, being 48 min (95% CI, -65 to -30) faster than obtaining and interpreting a chest radiograph.

#### **Recommendations**

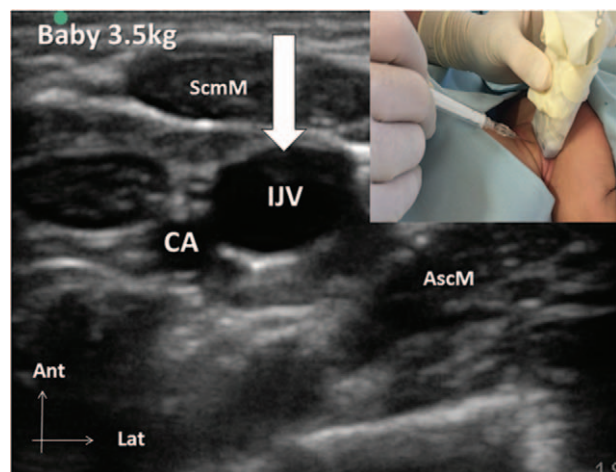
- (1) The quality of evidence on which to base recommendations is generally weak, with prospective cohort studies with a high degree of heterogeneity.
- (2) We recommend performing PLUS to rule out potential pleural-pulmonary complications (mainly pneumothorax) soon after the procedure in any difficult puncture of the subclavian or axillary vein and, particularly, if the patient complains of shortness of breath or discomfort that worsens after catheter placement **(1B)**.
- (3) We recommend using PLUS to monitor the development of a confirmed pleural-pulmonary complication or for follow-up of treatment **(1B)**.
- (4) We recommend ultrasound for diagnosis and follow-up of catheter-related thrombosis **(1C)**.

#### **Ultrasound-guided vascular cannulation in children**

The easy and well tolerated insertion of relatively large bore central venous catheters (i.e. 3 French size) is now possible, not only for children and adolescents but, thanks to ultrasound guidance, even in extremely preterm infants weighing well below 1 kg.<sup>153,154</sup> Such catheters enable blood sampling, monitoring and high flow infusions. These catheters may contribute to reduced mortality and improved outcomes.<sup>155</sup>

Both venous and arterial cannulation in small children have always been challenging, even in experienced hands, and are often associated with immediate life-threatening adverse events and long-term complications. With the introduction of ultrasound guidance, the rate of successful cannulation has significantly increased, even in small children; in addition, the occurrence of complications has been significantly reduced. This is mainly due to being able to scan and measure veins before cannulation, when the best vein can be chosen and venepuncture is then performed under real time direct ultrasound visualisation. Figure 6 shows a transverse view of the IJV in a paediatric patient. We found 1705 citations of abstracts and full-published articles relevant to the topic of vascular access in children. However, further relevant articles published after the window of the literature search were also included. From these, 92 papers were

Fig. 6



Out-of-plane view of the right internal jugular vein in a 3.5 kg baby. External view: 22-gauge needle with attached syringe aiming at the internal jugular vein. Probe positioned for the short axis view. Ultrasonographic image: IJV, internal jugular vein; CA, carotid artery; ScmM, sternocleidomastoid muscle; AscM, anterior scalene muscle.

selected for review, and 27 met the inclusion criteria to inform the current guidelines.

### Recommendations

- (1) For vascular access device placement in paediatric patients, we suggest the global use of ultrasound to assist all steps of the procedure that include preprocedural ultrasound evaluation of all possible options; recognition of possible local disease; ultrasound-guided real-time puncture; verification of the direction of guidewires and catheters in the vessel, and onwards towards the superior vena cava for centrally inserted central catheters, or onwards towards the inferior vena cava for femoral or groin catheters; verification of the correct position of the catheter tip; detection of possible postprocedural early and late complications (2B).

### Should ultrasound guidance be used during cannulation of the internal jugular vein for central venous line placement in children?

Our analysis of eight studies (two RCTs and five prospective cohort studies),<sup>155–162</sup> which included 949 individuals, showed moderate evidence that ultrasound-guided cannulation is more effective than landmarks or other techniques with a RR of 0.3 (95% CI, 0.14 to 0.62) in achieving a successful cannulation. Four of these studies (three cohort studies, one RCT)<sup>156,158,160,161</sup> included 642 patients in total and provided evidence that the time to achieve a successful first pass cannulation or overall time to cannulation was shorter with a mean difference of 6.91 (95% CI, 13.13 to 0.69) s shorter when USG is used, but

with a moderate grade of evidence. Finally, the incidence of complications was less when ultrasound guidance was used with a RR of 0.4 (95% CI, 0.23 to 0.70).<sup>156,160–162</sup> All the above-cited studies describe an out-of-plane cannulation technique of the IJV.

### Recommendations

- (1) The quality of evidence on which to base recommendations is generally weak, with relatively few small RCTs and prospective cohort studies that have a high degree of heterogeneity.
- (2) We recommend the use of ultrasound-guided cannulation for IJV cannulation in children, as it increases the success rate, reduces the time to successful cannulation and incidence of complications (1B).
- (3) Figure 6 show a transverse view of the IJV in a paediatric patient.

### Should ultrasound guidance be used during cannulation of the brachiocephalic vein for central venous line placement in children?

Our initial search identified 83 articles related to the brachiocephalic vein in children: eight were selected to inform this guideline. These eight prospective cohort studies,<sup>154,155,163–168</sup> all using an ultrasound-guided technique with no comparison with any other technique, provide evidence that the supraclavicular cannulation of the brachiocephalic vein is associated with an overall puncture success rate over 95%, and a first pass success rate of around 75%, with an inadvertent arterial injury rate of less than 1%. This panel of authors believes that in expert hands ultrasound-guided cannulation of the brachiocephalic vein in small infants and neonates is feasible and safe. Figure 7 shows the long axis view of the left brachiocephalic vein in an infant. There is some evidence (two retrospective case analyses and one prospective cohort study) that the cannulation of the left brachiocephalic vein is easier than the right.<sup>154,162,164</sup>

### Recommendations

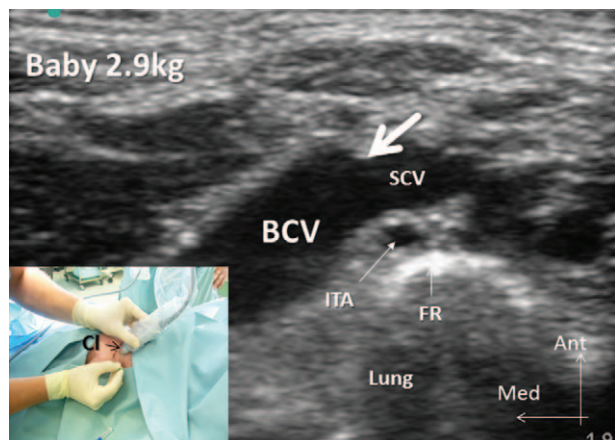
- (1) The quality of evidence on which to base recommendations is generally weak, with relatively few small prospective cohort studies that have a high degree of heterogeneity and some methodological problems.
- (2) We recommend ultrasound guidance for brachiocephalic vein cannulation only when used by experts (1C).

### Should ultrasound guidance be used during cannulation of the femoral vein for central venous line placement in children?

We identified 425 articles related to femoral vein cannulation in children and selected three to inform our guidelines.<sup>169–171</sup> Our analysis of these three RCTs, including 231 children (336 procedures), showed that ultrasound



Fig. 7



Long axis view of the left brachiocephalic vein. External view: Ultrasound probe placed in the left supraclavicular region to obtain the optimum long-axis view of the left brachiocephalic vein and puncture needle indicating the in-plane approach: Cl, clavicle. Ultrasonographic image: BCV, brachiocephalic vein; SCV, subclavian vein; FR, first rib; ITA, internal thoracic artery. White boldfaced arrow indicating the implied needle insertion.

guidance is marginally more effective than landmarks and/or other techniques for overall success with a RR (95% CI) of 0.45 (0.24 to 0.87), but the time to achieve a successful cannulation was not significantly different with a mean difference (95% CI) in cannulation time of 95.13 (238.91 to -48.64) s in favour of USG. In the 231 children,<sup>169–171</sup> there was minimal evidence that ultrasound guidance reduced the occurrence of complications RR (95% CI) 0.40 (0.11 to 1.42)%.

#### Recommendations

- (1) The quality of evidence on which to base recommendations is generally weak, with relatively few RCTs that have a high degree of heterogeneity.

We recommend the use of ultrasound guidance for femoral vein cannulation in children, as it increases the success rate (1C), with a tendency to reduce the risk of complications, without reducing the time of successful cannulation.

#### Should ultrasound guidance be used during cannulation of the radial artery for arterial line placement in children?

We identified 241 records as a result of the database search and 58 articles were selected as potentially relevant studies: five met the criteria for inclusion. Our analysis of these five RCTs,<sup>172–176</sup> which included 478 children undergoing arterial cannulation, showed that the use of ultrasound guidance increases the overall success rate with a RR (95% CI) of 0.61 (0.39 to 0.94), with a moderate grade of evidence.

*Eur J Anaesthesiol* 2020; **37**:344–376

#### Recommendation

- (1) The quality of evidence on which to base recommendations is generally weak, with relatively few RCTs that have a high degree of heterogeneity.
- (2) We recommend the use of ultrasound guidance for routine arterial cannulation in children, as it increases the success rate (1B).

#### Should ultrasound guidance be used during cannulation of peripheral veins for venous line placement in children?

Peripheral vein cannulation can be challenging in children, especially in small infants or patients with poorly visible or palpable peripheral veins. We found one RCT<sup>177</sup> comparing an ultrasound-guided technique with the palpation technique. Ultrasound guidance had a slightly higher overall success rate (42 vs. 38%,  $P = 0.08$ ), and significantly higher success rate in patients with difficult access (35 vs. 18%,  $P = 0.003$ ), but it took longer than the landmark technique (2.25 vs. 4 min,  $P < 0.001$ ). However, due to low external validity and intrinsic risk of bias, the grade of evidence was defined as low.

#### Recommendation

- (1) Due to the paucity of well conducted studies, we cannot recommend the routine use of ultrasound guidance for peripheral vein cannulation in paediatric patients. Some evidence suggests that the use of ultrasound by an experienced operator improves the success rate of difficult peripheral vein cannulation in children; in these circumstances, it may be of some benefit (2B).

#### Is the use of ultrasound useful in developing new approaches for vascular access in children?

There is some evidence to conclude that the use of ultrasound has contributed to the development of new approaches for paediatric vascular access. In particular, the approach to the brachiocephalic and subclavian vein via the supraclavicular region has only been developed since the introduction of point of care ultrasound into clinical practice. Children and neonates, both term and preterm, can take benefits from this recently described approach. There is weak evidence that the ultrasound-guided supraclavicular cannulation of the brachiocephalic vein or the subclavian vein may be the best option in children.<sup>167,168</sup>

#### Recommendations

- (1) We recommend further research to investigate which supraclavicular approach could be better by using ultrasound guidance.

#### Ultrasound-guided vascular cannulation: training

##### How should peri-operative ultrasound training on vascular access placement be performed?

Recently, some authors have suggested introducing the use of point-of-care and clinically integrated ultrasound

as a diagnostic tool and as a guide for interventional procedures into the medical school curriculum.<sup>178,179</sup> POCUS is now considered to be within the scope and practice of all healthcare providers, and consequently, it should now be integrated into our daily clinical practice.

Central venous catheterisation, arterial cannulation, diagnosis of pleural collections and pneumothorax, echocardiography, regional nerve blocks and other procedures are being increasingly performed using ultrasound by anaesthesiologists and intensivists.

For all these reasons, the definition of a proper and adequate training is mandatory and among our precise responsibilities.

To date, there is no high-quality evidence on how POCUS training should be performed. Indeed, with the exception of echocardiography, the suggested training for POCUS applied to emergency medicine and critical care (different societies)<sup>180–184</sup> is based only on minimal requirements and it is mostly based on expert opinion.

Taking into consideration, the paradigm shift towards entrustable professional activities and the fact that most medical educational systems in Europe are turning from a time-based to a competence-based assessment, training in ultrasound should also be designed accordingly. There is an ongoing discussion that training in POCUS, both for diagnostic and interventional purposes, should be part of undergraduate training and therefore should be incorporated into core professional activities.<sup>185–187</sup>

Specifically, regarding the training on the use of ultrasound to guide vascular catheterisation, the majority of published papers<sup>188–191</sup> and the World Conference on Vascular Access consensus<sup>186</sup> suggest that such educational programmes should include at least formal didactic or web-based teaching of the foundations of ultrasound and anatomy, ultrasound-guided insertion procedures and the prevention of early and late complications. In addition, the initial hands on training should utilise laboratory training on models and tools for simulation practice.<sup>192</sup> Only if the trainee has met a minimum achievement level based on a checklist of skills in the laboratory/simulation phase should a supervised clinical phase occur and then, provided there has been adequate progress along the learning curve, a personal learning phase with distant supervision. Clinical competence should be determined by observation during clinical practice using a global rating scale rather than simply by the number of procedures performed.

One of the main objectives of our guidelines is to recommend a structured path for training, assessment and the certification of proficiency for anaesthesiologists and intensivists in the use of ultrasound.

Among the 68 articles on ultrasound education that were screened, only 24 met the inclusion criteria and very few

met the eligibility criteria.<sup>193–195</sup> Most papers analysed were single-centre experiences and, in the light of this, it was not possible to provide evidence. Accordingly, the Taskforce decided to perform a modified Delphi consensus method to achieve a consensus on the criteria for education and training in ultrasound.

### **Recommendations for training in ultrasound-guided vascular access**

General curriculum: for ultrasound-guided vascular access procedures, this should consist of

- (1) didactic group lectures or web-based teaching;
- (2) laboratory training which includes simulation training;
- (3) a clinical phase that includes both closely supervised and distant supervised learning.

Didactic general content should include the relevant ultrasound anatomy (both typical and variant presentations); ultrasound guidance; ultrasound assessment of veins, arteries and nerves; vein selection criteria; and complications that may occur. General knowledge of the available vascular devices and their selection and maintenance is of paramount importance for the trainee. Specific ultrasound knowledge of vessel characteristics and of the respiratory and cardiac systems should also be taught.

Didactic specific ultrasound content should consist of the physics of ultrasound, knobology, image optimisation and interpretation, anatomical ultrasound assessment of both normal and variant anatomy, and ultrasound artefacts and simulation skills training. Acknowledgment of the concepts of long and short axis, in-plane and out-of-plane visualisation of the needle, proper selection of the catheter/vein ratio is crucial in this setting. Regarding vascular access placement, education should include sonographic vascular and cardiac evaluation relevant for tip navigation and tip location techniques and PLUS for ruling-out respiratory complications.

Laboratory simulation is mandatory and should include at least two hands-on sessions: the first on ultrasound anatomy in healthy volunteers, discussing anatomical variability and simulating a decision-making process; the second focused on procedure simulation practice on simulators. Simulation practice on models should be structured with six to 12 steps of increasing difficulty. The main objective must be to develop operator confidence with image-mediated rather than eye-guided hand motion and coordination between hands working in different directions, with the nondominant hand holding the probe obtaining the best ultrasound image of the vessel, and the dominant operator hand holding the performing vessel puncture.

We provide an example of a seven-steps approach structure as follows:

Step 1: probe orientation and correct acquisition of the transverse scan of the simulated vessel

Step 2: hand stabilisation, static and dynamic evaluation of the vessel

Step 2a: the ulnar side of the hand rests on the phantom surface to avoid probe slipping

Step 2b: evaluate the diameter and depth of the vein

Step 2c: test vein compressibility and probe sliding to evaluate any change in venous depth and course

Step 3: shift to long axis scan of the vein

Step 4: static visualisation of the needle and its tip in the 'out-of-plane' and 'in-plane' view

Step 5: dynamic visualisation of the needle and its tip without a venous target

Step 6: techniques of ultrasound-guided venepuncture

Step 6a: 'out-of-plane' technique + short axis of the vessel

Step 6b: 'in-plane' technique performed using a short axis view of the vessel

Step 6c: 'in plane' technique by using a long axis view of the vessel

Step 6d: 'in-plane' technique performed using the oblique axis view of the vessel

Step 7: complete simulation of the procedure, which includes field preparation

Step 7a: ultrasound visualisation of the guidewire inside the vessel

Step 7b: dilator or micro-introducer insertion and its visualisation

Step 7c: catheter introduction and securing and ultrasound visualisation of catheter within the lumen.

It is advisable for a teaching institution to implement a targeted assessment after laboratory training and before the clinical phase of learning. Only trainees who pass this assessment should continue to the clinical aspects of their training. This approach could be incorporated into trainee's core professional activities.

Infection control related to ultrasound-guided vascular access placement should be incorporated in the teaching phase, in particular as regards sterile draping and complete ultrasound probe and connecting cable cover.

Supplemental Digital Content 5, <http://links.lww.com/EJA/A282> summarises the recommendations for training arising from the PERSEUS Delphi Consensus process.

### **How should the competency of a trainee be assessed for ultrasound-guided vascular access procedures?**

On the basis of our Delphi survey, this panel of experts recommends that after laboratory training and simulation, each trainee should pass a theoretical and a practical examination on a simulator before commencing clinical training. After an adequate clinical training, including supervised procedures performed on patients, the trainee must complete every step of the final assessment in order

to obtain the certificate of proficiency before undertaking the procedures alone, with distant supervision. It would be desirable if the training process is completed when the trainee demonstrates practical competency in a final assessment through a clinical audit that will be assessed using a global rating scale. Some authors suggest reviewing video recordings of trainees performing the procedure in order to assess competency.<sup>181</sup> This would also allow the identification and discussion of major issues, thus improving the education process.

The number of performed procedures, the duration of the clinical training and the rate of complications also determine competency. Procedural volume is an important factor in reducing complications as well as developing and maintaining clinical competence. Global rating scales should be used as formal evaluation instruments.

Before the decision on competency is made, we recommend that each trainee should perform at least 30 successful procedures within 12 months after the end of the theoretical-practical course and with a complications rate corresponding to that of experienced operators as published in literature.

### **Who can become a trainer?**

On the basis of the Delphi survey, this panel of experts identified a trainer/instructor as a person in a position of trust in the learning partnership who must also meet the following criteria:

- (1) be active in clinical practice
- (2) have competence in what he/she teaches
- (3) have knowledge of best practice and guidelines
- (4) have experience and motivation in education and training

Trainers should also be certified practitioners, actively participating in the development of quality indicators to measure outcomes of training. A trainer should be a safety and patient-orientated healthcare advocate, promoting the spread of the global use of ultrasound and awareness of catheter-related infections and thrombosis prevention culture as well.

The instructor/supervisor should be an active practitioner who is in clinical practice with competency and knowledge of best practice and clinical excellence demonstrated through participation in performance of education and with publication activities in the field of peri-operative ultrasonography.

### **Nontechnical skills and feedback**

It is usually mistakenly understood both by teachers and learners that ultrasound-guided procedures and skills are only about training and performing the procedure. However, various nontechnical skills should not be neglected as diagnosis and management

of catheter-related complications such as catheter-related thrombosis and catheter-related infections. Trainees should be actively involved in various peri-operative activities through all phases of their patient's peri-operative course. Catheter-related management should be included in the core curriculum of training for ultrasound-guided vascular access, with a focus on the main complications such as infection control and prevention of catheter-related thrombosis. Areas of particular importance are teamwork, communication, assessment of patients, management of various complications, follow-up during the peri-operative period and so on.<sup>182</sup> Another highly important part of the whole training process is the giving and receiving of feedback, which significantly improves the clinical performance of the learners.<sup>183</sup> Feedback from trainees to teachers and instructors also helps to improve teaching quality and supports the attitude of trainee orientated medical education. Improvement of nontechnical skills, giving and receiving feedback should be supported and encouraged by the programme directors, instructors and learners.

### Final remarks

The data shown in the PERSEUS guidelines on vascular access aim to answer two main clinical questions: is ultrasound guidance better than the landmark technique or any other non-USG technique and how should anaesthesiologists be trained to perform these procedures properly? The number of papers about the use of ultrasound in the peri-operative period is too extensive to present the results in a single paper, so that this first part has been dedicated exclusively to ultrasound guidance for vascular access and a second guideline will be devoted to ultrasound in regional and neuraxial anaesthesia

In addressing these questions, evidence published after 2010 was screened and evaluated in accordance with GRADE in order to provide a hierarchy of recommendations on different topics. We took a systematic approach to searching for all available relevant evidence and this information was interpreted by experts in the field in order to provide a comprehensive and useful guideline that clinicians across Europe can easily implement in their various clinical settings.

A systematic review with a predefined protocol and transparent methodology systematically gathers evidence to answer a specific clinical question, and is combined with data-synthesis (meta-analysis) that is dependent on the availability of data and the level of heterogeneity. Our approach differs from this, as a systematic review does not make recommendations. Due to the magnitude of the topics covered in the preparation of the guideline, containing several hundred specific PICOT questions, and the overall poor quality of evidence, there was little scope for appropriate data-synthesis. We performed some meta-analyses (whenever it was possible) to provide an overview of some of the data provided in the clinical studies.

Some of these showed statistical significance but with no clinical relevance, as they did not properly reflect the settings and the experience of the operators involved in the study.

The current recommendations cover the most common questions regarding the use of ultrasound guidance for vascular access in the peri-operative period, but we understand that there may be other issues that are not discussed.

In the past years, some similar systematic reviews<sup>12,17,45</sup> did not reach a sufficient level of evidence to prefer USG over landmark techniques so the aim of the current guideline is to provide a consensus opinion on the use of USG in everyday clinical practice especially with regard to training where the evidence is scarce and not supported by clinical trials.

There has been some debate whether ultrasound guidance should be used routinely or whether it should be considered only in difficult patients (such as obese and paediatric patients, or where landmarks are missing). Whenever an ultrasound machine is available, vascular cannulation should be performed under ultrasound guidance, and as an ultrasound machine is available almost in every surgical and intensive care area, its use should be considered as the first line for intravenous cannulation. Considering ultrasound guidance as a second option only when landmark techniques fail will obviously increase the difficulties for ultrasound, as the presence of a haematoma or the decreased compliance of the patient may reduce the success of ultrasound-guided cannulation. We found similar results when ultrasound guidance was used for cannulation of the IJV, femoral vein and arterial accesses. Regarding the use of ultrasound guidance for brachiocephalic and subclavian vein cannulation and peripheral venous access, the evidence is still limited, but there are some studies that support the use of ultrasound guidance to improve the efficacy and safety of the procedure in these situations.

Ultrasound guidance can be considered well tolerated and applicable in almost all patients in the peri-operative setting when used by a competent operator. The only limitations are its use during life-threatening emergencies when there is no time to prepare the ultrasound machine and the intra-osseous route may still be considered the first choice if a peripheral venous line cannot be easily inserted, or in the presence of subcutaneous air that can make the ultrasound visualisation of underlying vessels very difficult.

The use of ultrasound is not limited to the act of cannulating a vessel, it should be used to match the vein with the catheter to be inserted, so as to avoid possible thrombotic risks due to the excessive size of the catheter compared with the size of the vein.<sup>188</sup> After the vascular device has been placed, ultrasound should be used to

check for the correct location of the catheter tip and possible life-threatening complications.

This Task Force emphasises the importance of a proper training for achieving competency and full proficiency before performing any ultrasound-guided vascular procedure. This guideline aims to help to design and establish a training and evaluation programme that could be consistent between European countries. There are no hard data or RCTs on how to train and educate trainees. Our recommendations are based on the current practice in the many centres around Europe involved in education on POCUS. The ‘see-one, do-one, teach-one’ philosophy should now be considered obsolete and new objective learning techniques are used to educate anaesthesiologists and intensivists on how to use ultrasound in the peri-operative period. Two more topics that need further investigation are, first, How can anaesthesiologists and intensivists who are already highly skilled in the practice of vascular device placement by landmark techniques be trained to at least the same level of proficiency in the use of ultrasound. Second, how can new ultrasound trained anaesthetists, with little or no experience or confidence in landmark techniques, be brought up to the same level of skill in using landmark techniques as the current cohort of nonultrasound trained anaesthetists? Indeed, should we continue teaching the landmark techniques to our young trainees or should we move to an ultrasound-based teaching, which in the end may also benefit the performance of the landmark technique when the latter is inevitable?

Unfortunately, an increasing number of studies are now comparing only different ultrasound techniques (e.g. two or three different visualisations), and for this reason, a real comparison of ultrasound guidance with other techniques is becoming more difficult.<sup>189</sup>

Considering the economic aspects of providing sufficient ultrasound machines in every hospital, the task force is aware that there will inevitably be some differences in national guidelines. The PERSEUS guideline is not intended to replace possible national or institutional guidelines, although we hope that it may help to develop a unified approach among different European countries especially with regard to the teaching of ultrasound vascular cannulation. The task force aimed to summarise the scientific background on ultrasound-guided vascular placement in the peri-operative area in the hope that this might help each European anaesthesiologist in their daily practice and support the purchase of ultrasound equipment when this is not available.

Guidelines can be perceived as ‘friend or foe’ according to the availability of the equipment and experienced ultrasound trained anaesthesiologists, but we appreciate the fact that our recommendations should be evaluated and sometimes adapted before their implementation in different European countries. Some countries and national societies may decide to assess the evidence

and recommendations differently. We emphasise that our recommendations can be adopted, modified or even not implemented, depending on institutional or national requirements and legislation and local availability of devices, resources and training.

POCUS is just the start of a clinical developing process that will change the practice of medicine and the delivery of healthcare.<sup>2</sup>

### Acknowledgements related to this article

**Assistance with these guidelines:** We thank Janne Vendt, Cochrane Anaesthesia, Critical and Emergency Care Group (ACE), Anaesthesiologisk afd I Herlev Hospital Herlev, Denmark for the literature search and Amanda Perry, Cleveland Clinic Abu Dhabi, for her assistance as a professional photographer.

**Financial support and sponsorship:** literature search has been funded and supported by the ESA.

**Conflicts of interest:** EB received sponsored ultrasound machines from Sonosite (Bothell, Washington, United States) and Mindray (Shenzhen, China) for organizing educational course. All other authors do not report any conflict of interest related to this topic.

**List of external reviewers:** Andrew Bodenham, Consultant Anaesthetist, Leeds General Infirmary, Leeds (UK), Fulvio Pinelli, Consultant Anaesthetist, Careggi Hospital, Florence (Italy), Wolfram Schummer, Consultant Anaesthetist, Helios Spital Überlingen (Austria), Jack Le Donne, Medical Director, Chesapeake Vascular Access, Baltimore (USA), Bernd Saugel, Consultant Anaesthetist, University Medical Center Hamburg-Eppendorf, Hamburg (Germany).

### References

- Schwartz PJ, Breithardt G, Howard A, *et al.* Task Force Report: the legal implications of medical guidelines: a Task Force of the European Society of Cardiology. *Eur Heart J* 1999; **20**:1152–1157.
- Moore CL, Copel JA. Point-of-care ultrasonography. *N Engl J Med* 2011; **364**:749–757.
- Shankar H, Pagel PS. Potential adverse ultrasound-related biological effects: a critical review. *Anesthesiology* 2011; **115**:1109–1124.
- Toms DA. The mechanical index up, and the ALARA principle. *J Ultrasound Med* 2006; **25**:560–561.
- Food and Drug Administration. Marketing clearance of diagnostic ultrasound systems and transducers: draft guidance for Industry and Food and Drug Administration Staff. 2017. <https://www.fda.gov/ucm/groups/fdagovpublic/@fdagovmeddevgen/documents/document/ucm578118.pdf> [Accessed 16 August 2019].
- Abbate LP, Wang M, Sriganesh K, *et al.* Framing of research question using the PICOT format in randomised controlled trials of venous ulcer disease: a protocol for a systematic survey of the literature. *BMJ Open* 2016; **6**:e013175.
- Higgins JPT, Green S. Cochrane handbook for systematic reviews of interventions version 5.1.0 [updated March 2011]. The Cochrane Collaboration, 2011. <http://handbook.cochrane.org> [Accessed 25 November 2019].
- Fitch KBS, Aguilar MD, Burnand B, *et al.* *The RAND/UCLA appropriateness method user's manual*. RAND: Santa Monica; 2001.
- Diamond IR, Grant RC, Feldman BM, *et al.* Defining consensus: a systematic review recommends methodologic criteria for reporting of Delphi studies. *J Clin Epidemiol* 2014; **67**:401–409.
- De Robertis E, Longrois D. To streamline the guideline challenge: the European Society of Anaesthesiology policy on guidelines development. *Eur J Anaesthesiol* 2016; **33**:794–799.
- National Institute for Clinical Excellence. NICE technology appraisal guidance No 49: guidance on the use of ultrasound locating devices for placing central venous catheters. London: NICE; September 2002. [http://www.nice.org.uk/pdf/ultrasound\\_49\\_GUIDANCE.pdf](http://www.nice.org.uk/pdf/ultrasound_49_GUIDANCE.pdf) [Accessed 16 August 2019].

- 12 Lamperti M, Bodenham AR, Pittiruti M, *et al.* International evidence-based recommendations on ultrasound-guided vascular access. *Intensive Care Med* 2012; **38**:1105–1117.
- 13 American Society of Anesthesiology. Practice guidelines for central venous access: a report by the American Society of Anesthesiologists Task Force on Central Venous Access. *Anesthesiology* 2012; **116**:539–573.
- 14 Bodenham A, Babu S, Bennett J, *et al.* Association of anaesthetists of Great Britain and Ireland: safe vascular access 2016. *Anaesthesia* 2016; **71**:573–585.
- 15 Brass P, Hellmich M, Kolodziej L, *et al.* Ultrasound guidance versus anatomical landmarks for subclavian or femoral vein catheterization. *Cochrane Database Syst Rev* 2015; **1**:CD011447.
- 16 Spencer TR, Pittiruti M. Rapid Central Vein Assessment (RaCeVA): a systematic, standardized approach for ultrasound assessment before central venous catheterization. *J Vasc Access* 2019; **20**:243–249.
- 17 Brass P, Hellmich M, Kolodziej L, *et al.* Ultrasound guidance versus anatomical landmarks for internal jugular vein catheterization. *Cochrane Database Syst Rev* 2015; **1**:CD006962.
- 18 Nazari I, Musavi M, Alavi M. Comparing outcomes and complication of central venous cannulation using both conventional and ultrasound guide. *Biosci Biotechnol Res Asia* 2015; **12**:2167–2171.
- 19 Airapetian N, Maizel J, Langelle F, *et al.* Ultrasound-guided central venous cannulation is superior to quick-look ultrasound and landmark methods among inexperienced operators: a prospective randomized study. *Intensive Care Med* 2013; **39**:1938–1944.
- 20 Agarwal A, Singh D, Singh A. Ultrasonography: a novel approach to central venous cannulation. *Indian J Crit Care Med* 2009; **13**:213–216.
- 21 Karakitsos D, Labropoulos LN, De Groot E, *et al.* Real-time ultrasound-guided catheterisation of the internal jugular vein: a prospective comparison with the landmark technique in critical care patients. *Crit Care* 2006; **10**:R162.
- 22 Fathi M, Izanloo A, Jahanbakhsh S, *et al.* Central venous cannulation of the internal jugular vein using ultrasound-guided and anatomical landmark techniques. *Anesth Pain Med* 2016; **6**:e35803.
- 23 Bansal R, Agarwal SK, Tiwari SC, Dash SC. A prospective randomized study to compare ultrasound-guided with non ultrasound-guided double lumen internal jugular catheter insertion as a temporary hemodialysis access. *Ren Fail* 2005; **27**:561–564.
- 24 Dolu HGS, Sahin L, Ozen O, Eken L. Comparison of an ultrasound-guided technique versus a landmark-guided technique for internal jugular vein cannulation. *J Clin Monit Comput* 2014; **29**:177–182.
- 25 Karimi-Sari H, Faraji M, Mohazzab Torabi S, Asjodi G. Success rate and complications of internal jugular vein catheterization with and without ultrasonography guide. *Nurs Midwifery Stud* 2014; **3**:e23204.
- 26 Lee DW, Kim KH, Lee MG, *et al.* Ultrasonography assisted internal jugular central vein catheterization in the emergency department: comparison of methods. *J Korean Soc Emerg Med* 2009; **20**:409–414.
- 27 Leung J, Duffy M, Finckh A. Real-time ultrasonographically-guided internal jugular vein catheterization in the emergency department increases success rates and reduces complications: a randomized, prospective study. *Ann Emerg Med* 2006; **48**:540–547.
- 28 Milling TJ Jr, Rose J, Briggs WM, *et al.* Randomized, controlled clinical trial of point-of-care limited ultrasonography assistance of central venous cannulation: the Third Sonography Outcomes Assessment Program (SOAP-3) Trial. *Crit Care Med* 2005; **33**:1764–1769.
- 29 Palepu GB, Deven J, Subrahmanyam M, Mohan S. Impact of ultrasonography on central venous catheter insertion in intensive care. *Indian J Radiol Imaging* 2009; **19**:191–198.
- 30 Rando K, Castelli J, Pratt JP, *et al.* Ultrasound-guided internal jugular vein catheterization: a randomized controlled trial. *Heart Lung Vessel* 2014; **6**:13–23.
- 31 Ray BR, Mohan V, Kashyap L, *et al.* Internal jugular vein cannulation: a comparison of three techniques. *J Anaesthesiol Clin Pharmacol* 2013; **29**:367–371.
- 32 Riaz A, Khan R, Salim F. Ultrasound guided internal jugular venous cannulation: comparison with land-mark technique. *J Coll Physicians Surg Pak* 2015; **25**:315–319.
- 33 Schummer W, Schummer C, Tuppatsch H, *et al.* Ultrasound-guided central venous cannulation: is there a difference between Doppler and B-mode ultrasound? *J Clin Anesth* 2006; **18**:167–172.
- 34 Serafimidis K, Sakorafas GH, Konstantoudakis G, *et al.* Ultrasound-guided catheterization of the internal jugular vein in oncologic patients; comparison with the classical anatomic landmark technique: a prospective study. *Int J Surg* 2009; **7**: 526–528.
- 35 Shrestha BR, Gautam B. Ultrasound versus the landmark technique: a prospective randomized comparative study of internal jugular vein cannulation in an intensive care unit. *J Nepal Med Assoc* 2011; **51**:56–61.
- 36 Tagliari AP, Staub FL, Guimaraes JR, *et al.* Evaluation of three different techniques for insertion of totally implantable venous access device: a randomized clinical trial. *J Surg Oncol* 2015; **112**:56–59.
- 37 Turker G, Kaya FN, Gurbet A, *et al.* Internal jugular vein cannulation: an ultrasound-guided technique versus a landmark-guided technique. *Clinics* 2009; **64**:989–992.
- 38 Wang Y, Wang P. Role of 'non real-time' ultrasound localization in central venous catheterization of hemodialysis patients. *Nephrol Dial Trans* 2015; **30**:ii378.
- 39 Parienti JJ, Mongardon N, Mégarbane B, *et al.* 3SITES Study Group. Intravascular complications of central venous catheterization by insertion site. *N Engl J Med* 2015; **373**:1220–1229.
- 40 Alic Y, Torgay A, Pirat A. Ultrasound-guided catheterization of the subclavian vein: a prospective comparison with the landmark technique in ICU patients. *Crit Care* 2009; **13** (Suppl 1):S80.
- 41 Fragou M, Gravvanis A, Dimitriou V, *et al.* Real-time ultrasound-guided subclavian vein cannulation versus the landmark method in critical care patients: a prospective randomized study. *Crit Care Med* 2011; **39**:1607–1612.
- 42 Gualtieri E, Deppe SA, Sipperly ME, Thompson DR. Subclavian venous catheterization: greater success rate for less experienced operators using ultrasound guidance. *Crit Care Med* 1995; **23**:692–697.
- 43 Oh AY, Jeon YT, Choi EJ, *et al.* The influence of the direction of J-tip on the placement of a subclavian catheter: real time ultrasound-guided cannulation versus landmark method, a randomized controlled trial. *BMC Anesthesiol* 2014; **14**:11.
- 44 Campbell CJ, Joshua A, Medak A, *et al.* Is ultrasound-guided subclavian vein cannulation more successful than traditional methods? Academic Emergency Medicine Conference: 2011 Annual Meeting of the Society for Academic Emergency Medicine, SAEM; May 2011; Boston, MA. pp. S211 [Accessed June 1-5, 2011].
- 45 Lalu MM, Fahad A, Ahmed O, *et al.* Canadian perioperative anesthesia clinical trials group. Ultrasound-guided subclavian vein catheterization: a systematic review and meta-analysis. *Crit Care Med* 2015; **43**:1498–1507.
- 46 Milone M, Di Minno G, Di Minno MN, *et al.* The real effectiveness of ultrasound guidance in subclavian venous access. *Ann Ital Chir* 2010; **81**:331–334.
- 47 Perbet S, Grimaldi F, Pereira B, *et al.* Subclavian central venous catheters guidance and examination by ultrasound: a randomized controlled study versus landmark method. *JCMx* 2015; **3** (Suppl 1):A603.
- 48 Glen H, Lang I, Christie L. Infraclavicular axillary vein cannulation using ultrasound in a mechanically ventilated general intensive care population. *Anaesth Intensive Care* 2015; **43**:635–640.
- 49 Khanna AK. Axillary vein cannulation for central access: a newer look below the clavicle!. *J Anaesthesiol Clin Pharmacol* 2017; **33**:289–290.
- 50 Xu JX, Wang HZ, Ren H, *et al.* Clinical application of ultrasound guided central venous catheterization via the axillary vein. *Chin J Clin Nutr* 2013; **21**:163–167.
- 51 Liccardo M, Nocerino P, Gaia S, Ciardiello C. Efficacy of ultrasound-guided axillary/subclavian venous approaches for pacemaker and defibrillator lead implantation: a randomized study. *J Interv Card Electrophysiol* 2018; **51**:153–160.
- 52 Hilty WM, Hudson PA, Levitt MA, Hall JB. Real-time ultrasound guided femoral vein catheterization during cardiopulmonary resuscitation. *Ann Emerg Med* 1997; **29**:331–337.
- 53 Kwon TH, Kim YL, Cho DK. Ultrasound-guided cannulation of the femoral vein for acute haemodialysis access. *Nephrol Dial Trans* 1997; **12**:1009–1012.
- 54 Powell JT, Mink JT, Nomura JT, *et al.* Ultrasound-guidance can reduce adverse events during femoral central venous cannulation. *J Emerg Med* 2014; **46**:519–524.
- 55 Zollo A, Cavatorta F, Galli S. Ultrasound-guided cannulation of the femoral vein for acute hemodialysis access with silicone catheters. *J Vasc Access* 2001; **2**:56–59.
- 56 Prabhu MV, Juneja D, Gopal PB, *et al.* Ultrasound-guided femoral dialysis access placement: a single-center randomized trial. *Clin J Am Soc Nephrol* 2010; **5**:235–239.
- 57 Errahmouni A, Bun SS, Latcu DG, Saoudi N. Ultrasound-guided venous puncture in electrophysiological procedures: a safe method, rapidly learned. *Pacing Clin Electrophysiol* 2014; **37**:1023–1028.
- 58 Rodríguez Muñoz D, Franco Diez E, Moreno J, *et al.* Wireless ultrasound guidance for femoral venous cannulation in electrophysiology: impact on safety, efficacy, and procedural delay. *Pacing Clin Electrophysiol* 2015; **38**:1058–1065.
- 59 Wynn GJ, Haq I, Hung J, *et al.* Improving safety in catheter ablation for atrial fibrillation: a prospective study of the use of ultrasound to guide vascular access. *J Cardiovasc Electrophysiol* 2014; **25**:680–685.

- 60 Gorski L, Hadaway L, Hagle M, et al. Infusion therapy standards of practice. *J Infus Nurs* 2016; **39** (15):S1–S159.
- 61 Sanfilippo F, Noto A, Martucci G, et al. Central venous pressure monitoring via peripherally or centrally inserted central catheters: a systematic review and meta-analysis. *J Vasc Access* 2017; **18**:273–278.
- 62 van Loon FHJ, Puijin L, Houterman S, Bouwman ARA. Development of the A-DIVA Scale: a clinical predictive scale to identify difficult intravenous access in adult patients based on clinical observations. *Medicine (Baltimore)* 2016; **95**:e3428.
- 63 Aponte H, Acosta S, Rigamonti D, et al. The use of ultrasound for placement of intravenous catheters. *AANA J* 2007; **75**:212–216.
- 64 Kerforne T, Petitpas F, Frasca D, et al. Ultrasound-guided peripheral venous access in severely ill patients with suspected difficult vascular puncture. *Chest* 2012; **141**:279–280.
- 65 Riker MW, Kennedy C, Winfrey BS, et al. Validation and refinement of the difficult intravenous access score: a clinical prediction rule for identifying children with difficult intravenous access. *Acad Emerg Med* 2011; **18**:1129–1134.
- 66 Fields JM, Dean AJ, Todman RW, et al. The effect of vessel depth, diameter, and location on ultrasound-guided peripheral intravenous catheter longevity. *Am J Emerg Med* 2012; **30**:1134–1140.
- 67 Keyes LE, Frazee BW, Snoey ER, et al. Ultrasound-guided brachial and basilic vein cannulation in emergency department patients with difficult intravenous access. *Ann Emerg Med* 1999; **34**:711–714.
- 68 Costantino TG, Kirtz JF, Satz WA. Ultrasound-guided peripheral venous access vs. the external jugular vein as the initial approach to the patient with difficult vascular access. *J Emerg Med* 2010; **39**:462–467.
- 69 Vitto MJ, Mieres M, Vitto CM, Evans DP. Perceived difficulty and success rate of standard versus ultrasound-guided peripheral intravenous cannulation in a novice study group: a randomized crossover trial. *J Ultrasound Med* 2016; **35**:895–898.
- 70 McCarthy ML, Shokooji H, Boniface KS, et al. Ultrasonography versus landmark for peripheral intravenous cannulation: a randomized controlled trial. *Ann Emerg Med* 2016; **68**:10e8.
- 71 Bauman M, Braude D, Crandall C. Ultrasound-guidance vs. standard technique in difficult vascular access patients by ED technicians. *Am J Emerg Med* 2009; **27**:135–140.
- 72 Costantino TG, Parikh AK, Satz WA, Fojtik JP. Ultrasonography-guided peripheral intravenous access versus traditional approaches in patients with difficult intravenous access. *Ann Emerg Med* 2005; **46**:456–461.
- 73 Gong P, Huang XE, Chen CY, et al. Comparison of complications of peripherally inserted central catheters with ultrasound guidance or conventional methods in cancer patients. *Asian Pac J Cancer Prev* 2012; **13**:1873–1875.
- 74 Ismailoglu EG, Zaybak A, Akarca FK, Kiyan S. The effect of the use of ultrasound in the success of peripheral venous catheterisation. *Int Emerg Nurs* 2015; **23**:89–93.
- 75 Stokowski G, Steele D, Wilson D. The use of ultrasound to improve practice and reduce complication rates in peripherally inserted central catheter insertions: final report of investigation. *J Infus Nurs* 2009; **32**:145–155.
- 76 Bhurani D. Ultrasound guided peripherally inserted central venous catheterization (PICC) by microintroducer technique: a new experience. *Indian J Hematol Blood Transfus* 2013; **29**:191–277.
- 77 Weiner SG, Sarff A, Esener DE, et al. Single-operator ultrasound-guided intravenous line placement by emergency nurses reduces the need for physician intervention in patients with difficult-to-establish intravenous access. *J Emerg Med* 2013; **44**:653–660.
- 78 Darvish AH, Shroof SD, Mostofi MB, Weiner S. Single-operator ultrasound-guided IV placement by emergency nurses. *J Emerg Med* 2013; **44**:653–660.
- 79 Pappas NL, Michaud TE, Wolbers RM, et al. Ultrasound guidance as a rescue technique for peripheral intravenous cannulation. C104-1878, 1-16. 2006. Bethesda, MD: Uniformed Services University of the Health Sciences. 9-11-2012. <https://www.ena.org/practice-research/research/CPG/Documents/DifficultIVAAccessCPG.pdf>. [Accessed 16 August 2019].
- 80 Stein J, George B, River G, et al. Ultrasonographically guided peripheral intravenous cannulation in emergency department patients with difficult intravenous access: a randomized trial. *Ann Emerg Med* 2009; **54**:33–40.
- 81 Biffi R, Orsi F, Pozzi S, et al. Best choice of central venous insertion site for the prevention of catheter-related complications in adult patients who need cancer therapy: a randomized trial. *Ann Oncol* 2009; **20**:935–940.
- 82 Tamura A, Sone M, Ehara S, et al. Is ultrasound-guided central venous port placement effective to avoid pinch-off syndrome? *J Vasc Access* 2014; **15**:311–316.
- 83 Biffi R, Pozzi S, Bonomo G. Cost effectiveness of different central venous approaches for port placement and use in adult oncology patients: evidence from a randomized three-arm trial. *Ann Surg Oncol* 2014; **21**:3725–3731.
- 84 Pittiruti M, Hamilton H, Biffi R, et al. ESPEN Guidelines on parenteral nutrition: central venous catheters (access, care, diagnosis and therapy of complications). *Clin Nutr* 2009; **28**:365–377.
- 85 Pittiruti M, Bertollo D, Briglia E, et al. Intracavitary ECG method for positioning the tip of central venous catheters: results of an Italian multicenter study. *J Vasc Access* 2012; **13**:357–365.
- 86 Scheer BV, Perel A, Pfeiffer UJ. Clinical review: complications and risk factors of peripheral arterial catheters used for haemodynamic monitoring in anaesthesia and intensive care medicine. *Critical Care* 2002; **6**:198–204.
- 87 Thomas F, Burke JP, Parker J, et al. The risk of infection related to radial vs femoral sites for arterial catheterization. *Crit Care Med* 1983; **11**:807–812.
- 88 Abu-Omar Y, Mussa S, Anastasiadis K, et al. Duplex ultrasonography predicts safety of radial artery harvest in the presence of an abnormal Allen test. *Ann Thorac Surg* 2004; **77**:116–119.
- 89 Habib J, Baetz L, Satiani B. Assessment of collateral circulation to the hand prior to radial artery harvest. *Vasc Med* 2012; **17**:352–361.
- 90 Bobbia X, Grandpierre RG, Claret PG, et al. Ultrasound guidance for radial arterial puncture: a randomized controlled trial. *Am J Emerg Med* 2013; **31**:810–815.
- 91 Burad J, Date R, Kodange S, et al. Comparison of conventional and ultrasound guided techniques of radial artery cannulation in different haemodynamic subsets: a randomised controlled study. *Intensive Care Med* 2017; **43**:140–141.
- 92 Hansen MA, Juhl-Olsen P, Thorn S, et al. Ultrasonography-guided radial artery catheterization is superior compared with the traditional palpation technique: a prospective, randomized, blinded, crossover study. *Acta Anaesthesiol Scand* 2014; **58**:446–452.
- 93 Levin PD, Sheinen O, Gozal Y. Use of ultrasound guidance in the insertion of radial artery catheters. *Crit Care Med* 2003; **31**:481–484.
- 94 Nasreen A, Khuwaja A, Akhtar P, et al. A randomized comparison of ultrasound guided versus direct palpation method of radial artery cannulation techniques in adult patients undergoing open heart surgery. *Anaesth Pain Inten Care* 2016; **20**:38–42.
- 95 Seto A, Roberts JS, Abu-Fadel MS, et al. Real-time ultrasound guidance facilitates transradial access: RAUST (Radial Artery access with Ultrasound Trial). *J Am Coll Cardiol* 2016; **8**:283–291.
- 96 Shiver S, Blaivas M, Lyon M. A prospective comparison of ultrasound-guided and blindly placed radial arterial catheters. *Acad Emerg Med* 2006; **13**:1275–1279.
- 97 Tangwiwat S, Pankla W, Rushatamukayanunt P, et al. Comparing the success rate of radial artery cannulation under ultrasound guidance and palpation technique in adults. *J Med Assoc Thai* 2016; **99**:505–510.
- 98 Ueda K, Bayman EO, Johnson C, et al. A randomised controlled trial of radial artery cannulation guided by Doppler vs. palpation vs. ultrasound. *Anaesthesia* 2015; **70**:1039–1044.
- 99 Zaremski L, Quesada R, Kovacs M, et al. Prospective comparison of palpation versus ultrasound-guided radial access for cardiac catheterization. *J Invasive Cardiol* 2013; **25**:538–542.
- 100 Gedikoglu M, Oguzkurt L, Gur S, et al. Comparison of ultrasound guidance with the traditional palpation and fluoroscopy method for the common femoral artery puncture. *Catheter Cardiovasc Interv* 2013; **82**:1187–1192.
- 101 Seto AH, Abu-Fadel MS, Sparling JM, et al. Real-time ultrasound guidance facilitates femoral arterial access and reduces vascular complications: FAUST (Femoral Arterial Access With Ultrasound Trial). *JACC Cardiovasc Interv* 2010; **3**:751–758.
- 102 Li X, Fang G, Yang D, et al. Ultrasonic technology improves radial artery puncture and cannulation in intensive care unit (ICU) shock patients. *Med Sci Monit* 2016; **22**:2409–2416.
- 103 Peters C, Schwarz SK, Yarnold CH, et al. Ultrasound guidance versus direct palpation for radial artery catheterization by expert operators: a randomized trial among Canadian cardiac anesthesiologists. *Can J Anaesth* 2015; **62**:1161–1168.
- 104 Seto AH, Roberts J, Abu-Fadel MS. Real-time ultrasound guidance facilitates transradial access: RAUST (Radial Artery access with Ultrasound Trial). *JACC Cardiovasc Interv* 2015; **8**:283–291.
- 105 Tremblay-Gravel M, Marquis-Gravel M, Lévesque J, et al. Comparison of anatomical versus ultrasound-guided techniques for femoral artery access in patients undergoing coronary angiography: a randomized single-blinded trial. *Can J Cardiol* 2015; **31**:s25–s26.
- 106 Abdalla UE, Elmaadawey A, Kandeel A. Oblique approach for ultrasound-guided radial artery catheterization vs transverse and longitudinal approaches, a randomized trial. *J Clin Anesth* 2017; **36**:98–101.

- 107 Berk D, Gurkan Y, Kus A, *et al.* Ultrasound-guided radial arterial cannulation: long-axis/in-plane versus short-axis/out-of-plane approaches. *J Clin Monit Comput* 2013; **27**:319–324.
- 108 Stone MB, Moon C, Sutijono D, Blaivas M. Needle tip visualization during ultrasound-guided vascular access: short-axis vs long-axis approach. *Am J Emerg Med* 2010; **28**:343–347.
- 109 Quan ZF, Ming T, Ping C, *et al.* Modified short-axis out-of-plane ultrasound versus conventional long-axis in-plane ultrasound to guide radial artery cannulation: a randomized controlled trial. *Anesth Analg* 2014; **119**:163–169.
- 110 Song IK, Choi J, Lee JH, *et al.* Short-axis/out-of-plane or long-axis/in-plane ultrasound-guided arterial cannulation in children: a randomised controlled trial. *Eur J Anaesthesiol* 2016; **33**:522–527.
- 111 Sethi S, Maitra S, Saini V, *et al.* Comparison of short-axis out-of-plane versus long-axis in-plane ultrasound-guided radial arterial cannulation in adult patients: a randomized controlled trial. *J Anesth* 2017; **31**:89–94.
- 112 Fuda G, Denault A, Deschamps A, *et al.* Risk factors involved in central-to-radial arterial pressure gradient during cardiac surgery. *Anesth Analg* 2016; **122**:624–632.
- 113 Gebhard RE, Szmuk P, Pivalizza EG, *et al.* The accuracy of electrocardiogram-controlled central line placement. *Anesth Analg* 2007; **104**:65–70.
- 114 Pittiruti M, La Greca A, Scoppettuolo G. The electrocardiographic method for positioning the tip of central venous catheters. *J Vasc Access* 2011; **12**:280–291.
- 115 Biasucci DG, La Greca A, Scoppettuolo G, Pittiruti M. What's really new in the field of vascular access? Towards a global use of ultrasound. *Intensive Care Med* 2015; **41**:731–733.
- 116 Kim SC, Graff I, Sommer A, *et al.* Ultrasound-guided supraclavicular central venous catheter tip positioning via the right subclavian vein using a microconvex probe. *J Vasc Access* 2016; **17**:435–439.
- 117 Kim SC, Heinze I, Schmiedel A, *et al.* Ultrasound confirmation of central venous catheter position via a right supraclavicular fossa view using a microconvex probe: an observational pilot study. *Eur J Anaesthesiol* 2015; **32**:29–36.
- 118 Bedel J, Valle F, Mari A, *et al.* Guidewire localization by transthoracic echocardiography during central venous catheter insertion: a periprocedural method to evaluate catheter placement. *Intensive Care Med* 2013; **39**:1932–1937.
- 119 Syed M, Levinson A, Frost J, *et al.* Confirmation of central venous catheter placement using ultrasound. *Crit Care Med* 2012; **40**:59.
- 120 Meggiolaro M, Scatto A, Zorzi A, *et al.* Confirmation of correct central venous catheter position in the preoperative setting by echocardiographic 'bubble-test'. *Minerva Anesthesiol* 2015; **81**:989–1000.
- 121 Alonso-Quintela P, Oulego-Eroz I, Rodriguez-Blanco S, *et al.* Location of the central venous catheter tip with bedside ultrasound in young children: can we eliminate the need for chest radiography? *Pediatr Crit Care Med* 2015; **16**:e340–e345.
- 122 Lanza C, Russo M, Fabrizzi G. Central venous cannulation: are routine chest radiographs necessary after B-mode and colour Doppler sonography check? *Pediatr Radiol* 2006; **36**:1252–1256.
- 123 Park YH, Lee JH, Byon HJ, *et al.* Transthoracic echocardiographic guidance for obtaining an optimal insertion length of internal jugular venous catheters in infants. *Paediatr Anaesth* 2014; **24**:927–932.
- 124 Bavsikar AS, Khatib KI, Bhoi S, *et al.* Confirmation of endovenous placement of central catheter using the ultrasonographic 'bubble test'. *Indian J Crit Care Med* 2015; **19**:38–41.
- 125 Cortellaro F, Mellace L, Paglia S, *et al.* Contrast enhanced ultrasound vs chest x-ray to determine correct central venous catheter position. *Am J Emerg Med* 2014; **32**:78–81.
- 126 Duran-Gehring PE, Guirgis FW, McKee KC, *et al.* The bubble study: ultrasound confirmation of central venous catheter placement. *Am J Emerg Med* 2015; **33**:315–319.
- 127 Esmailian M, Azizkhani R, Najafi N. Saline flush versus chest x ray in confirmation of central venous catheter placement; a diagnostic accuracy study. *Emerg* 2017; **5**:e75.
- 128 Gekle R, Dubensky L, Haddad S, *et al.* Saline flush test: can bedside sonography replace conventional radiography for confirmation of above-the-diaphragm central venous catheter placement? *J Ultrasound Med* 2015; **34**:1295–1299.
- 129 Killu K, Parker A, Coba V, *et al.* Using ultrasound to identify the central venous catheter tip in the superior vena cava. *ICU Dir* 2010; **1**:220–222.
- 130 Matsushima K, Frankel HL. Bedside ultrasound can safely eliminate the need for chest radiographs after central venous catheter placement: CVC sono in the surgical ICU (SICU). *J Surg Res* 2010; **163**:155–161.
- 131 Maury E, Guglielminotti J, Alzieu M, *et al.* Ultrasonic examination: an alternative to chest radiography after central venous catheter insertion? *Am J Respir Crit Care Med* 2001; **164**:403–405.
- 132 Raman D, Sharma M, Moghekar A, *et al.* Utilization of thoracic ultrasound for confirmation of central venous catheter placement and exclusion of pneumothorax: a novel technique in real-time application. *J Intensive Care Med* 2019; **34**:594–598.
- 133 Vezzani A, Manca T, Vercelli A, *et al.* Ultrasonography as a guide during vascular access procedures and in the diagnosis of complications. *J Ultrasound* 2013; **16**:161–170.
- 134 Weekes AJ, Keller S, Efunu B, *et al.* Prospective comparison of ultrasound and CXR for confirmation of central vascular catheter placement. *Emerg Med J* 2016; **33**:176–180.
- 135 Wen M, Stock K, Heemann U, *et al.* Agitated saline bubble-enhanced transthoracic echocardiography: a novel method to visualize the position of central venous catheter. *Crit Care Med* 2014; **42**:e231–e233.
- 136 Zanolletti M, Coppa A, Bulletti F, *et al.* Verification of correct central venous catheter placement in the emergency department: comparison between ultrasonography and chest radiography. *Intern Emerg Med* 2013; **8**:173–180.
- 137 Amir R, Knio ZO, Mahmood F, Oren-Grinberg A. Ultrasound as a screening tool for central venous catheter positioning and exclusion of pneumothorax. *Crit Care Med* 2017; **45**:1192–1198.
- 138 Madhulika E, Manimala Rao S, Dnyaneshwar M, *et al.* Bedside ultrasound imaging for confirmation of central venous catheter position and to detect complications. *Indian J Crit Care Med* 2014; **18**:S26.
- 139 Lichtenstein DA, Mezière G, Lascols N, *et al.* Ultrasound diagnosis of occult pneumothorax. *Crit Care Med* 2005; **33**:1231–1238.
- 140 Sartori S, Tombesi P, Trevisani L, *et al.* Accuracy of transthoracic sonography in detection of pneumothorax after sonographically guided lung biopsy: prospective comparison with chest radiography. *Am J Roentgenol* 2007; **188**:37–41.
- 141 Hill SL, Edmisten T, Holtzman G, Wright A. The occult pneumothorax: an increasing diagnostic entity in trauma. *Am Surg* 1999; **65**:254–258.
- 142 International Liaison Committee on Lung Ultrasound (ILC-LUS) for the International Consensus Conference on Lung Ultrasound (ICC-LUS) VGVolpicelli G, Elbarbary M, Blaivas M, *et al.* International evidence-based recommendations for point-of-care lung ultrasound. *Intensive Care Med* 2012; **38**:577–591.
- 143 Soldati G, Testa A, Pignataro G, *et al.* The ultrasonographic deep sulcus sign in traumatic pneumothorax. *Ultrasound Med Biol* 2006; **32**:1157–1163.
- 144 Picardi M, Pagliuca S, Chirazzi F. Early ultrasonographic finding of septic thrombophlebitis is the main indicator of central venous catheter removal to reduce infection-related mortality in neutropenic patients with bloodstream infection. *Ann Oncol* 2012; **23**:2122–2128.
- 145 Blans MJ, Endeman H, Bosch FH. The use of ultrasound during and after central venous catheter insertion versus conventional chest x-ray after insertion of a central venous catheter. *Neth J Med* 2016; **74**:353–357.
- 146 Weekes AJ, Jonshon D, Keller SM, *et al.* Central vascular catheter placement evaluation using saline flush and bedside echocardiography. *Acad Emerg Med* 2014; **21**:65–72.
- 147 Kamalipour H, Ahmadi S, Kamali K, *et al.* Ultrasound for localization of central venous catheter: a good alternative to chest x-ray? *Anesth Pain Med* 2016; **6**:e38834.
- 148 Salimi F, Hekmatnia A, Shahabi J, *et al.* Evaluation of routine postoperative chest roentgenogram for determination of the correct position of permanent central venous catheters tip. *J Res Med Sci* 2015; **20**:89–92.
- 149 Santarsia G, Casino FG, Gaudiano V, *et al.* Jugular vein catheterization for hemodialysis: correct positioning control using real-time ultrasound guidance. *J Vasc Access* 2000; **1**:66–69.
- 150 Miccini M, Cassini D, Gregori M, *et al.* Ultrasound-guided placement of central venous port systems via the right internal jugular vein: are chest x-ray and/or fluoroscopy needed to confirm the correct placement of the device? *World J Surg* 2016; **40**:2353–2358.
- 151 Steinhagen F, Kanthak M, Kukuk G. Electrocardiography-controlled central venous catheter tip positioning in patients with atrial fibrillation. *J Vasc Access* 2018; **19**:528–534.
- 152 La Greca A, Biasucci DG, Emoli A, Pittiruti M. Improving the 'global use' of ultrasound for central venous access: a new supraclavicular scan by microconvex probe. *Crit Ultrasound J* 2014; **6** (Suppl 2):A11.
- 153 Montes-Tapia F, Rodríguez-Taméz A, Cura-Esquivel I, *et al.* Efficacy and safety of ultrasound-guided internal jugular vein catheterization in low birth weight newborn. *J Pediatr Surg* 2016; **51**:1700–1703.
- 154 Breschan C, Graf G, Jost R, *et al.* Ultrasound-guided supraclavicular cannulation of the right brachiocephalic vein in small infants: a consecutive, prospective case series. *Paediatr Anaesth* 2015; **25**:943–949.
- 155 Habas F, Baleine J, Milési C, *et al.* Supraclavicular catheterization of the brachiocephalic vein: a way to prevent or reduce catheter maintenance-related complications in children. *Eur J Pediatr* 2018; **177**:451–459.



- 156 Al Hamod DA, Zeidan S, Al Bizri A, *et al.* Ultrasound-guided central line insertion and standard peripherally inserted catheter placement in preterm infants: comparing results from prospective study in a single-center. *N Am J Med Sci* 2016; **8**:205–209.
- 157 Arai T, Yamashita M. Central venous catheterization in infants and children: small caliber audio-Doppler probe versus ultrasound scanner. *Paediatr Anaesth* 2005; **15**:858–861.
- 158 Bruzoni M, Slater B, Wall J, *et al.* A prospective randomized trial of ultrasound- vs landmark-guided central venous access in the pediatric population. *J Am Coll Surg* 2013; **216**:939–943.
- 159 Chuan WX, Wei W, Yu L. A randomized-controlled study of ultrasound prelocation vs anatomical landmark-guided cannulation of the internal jugular vein in infants and children. *Paediatr Anaesth* 2005; **15**:733–738.
- 160 Froehlich CD, Rigby MR, Rosenberg ES, *et al.* Ultrasound-guided central venous catheter placement decreases complications and decreases placement attempts compared with the landmark technique in patients in a pediatric intensive care unit. *Crit Care Med* 2009; **37**:1090–1096.
- 161 Leyvi G, Taylor DG, Reith E, Wasnick JD. Utility of ultrasound-guided central venous cannulation in pediatric surgical patients: a clinical series. *Paediatr Anaesth* 2005; **15**:953–958.
- 162 Oulego-Erroz I, González-Cortes R, García-Soler P, *et al.* RECANVA collaborative study. Ultrasound-guided or landmark techniques for central venous catheter placement in critically ill children. *Intensive Care Med* 2018; **44**:61–72.
- 163 Yoshida H, Kushikata T, Kitayama M, *et al.* Time-consumption risk of real-time ultrasound-guided internal jugular vein cannulation in pediatric patients: comparison with two conventional techniques. *J Anesth* 2010; **24**:653–655.
- 164 Breschan C, Platzer M, Jost R, *et al.* Ultrasound-guided supraclavicular cannulation of the brachiocephalic vein in infants: a retrospective analysis of a case series. *Paediatr Anaesth* 2012; **2**:1062–1067.
- 165 Rhondali O, Attouf R, Combet S, *et al.* Ultrasound-guided subclavian vein cannulation in infants: supraclavicular approach. *Paediatr Anaesth* 2011; **21**:1136–1141.
- 166 Avanzini S, Mameli L, Disma N, *et al.* Brachiocephalic vein for percutaneous ultrasound-guided central line positioning in children: a 20-month preliminary experience with 109 procedures. *Pediatr Blood Cancer* 2017; **64**:330–335.
- 167 Oulego-Erroz I, Muñoz-Lozón A, Alonso-Quintela P, Rodríguez-Nuñez A. Comparison of ultrasound guided brachiocephalic and internal jugular vein cannulation in critically ill children. *J Crit Care* 2016; **35**:133–137.
- 168 Byon HJ, Lee GW, Lee JH, *et al.* Comparison between ultrasound-guided supraclavicular and infraclavicular approaches for subclavian venous catheterization in children – a randomized trial. *Br J Anaesth* 2013; **111**:788–792.
- 169 Aouad MT, Kanazi GE, Abdallah FW, *et al.* Femoral vein cannulation performed by residents: a comparison between ultrasound-guided and landmark technique in infants and children undergoing cardiac surgery. *Anesth Analg* 2010; **111**:724–728.
- 170 Iwashima S, Ishikawa T, Ohzeki T. Ultrasound-guided versus landmark-guided femoral vein access in pediatric cardiac catheterization. *Pediatr Cardiol* 2008; **29**:339–342.
- 171 Law MA, Borasino S, McMahon WS, Alten JA. Ultrasound- versus landmark-guided femoral catheterization in the pediatric catheterization laboratory: a randomized-controlled trial. *Pediatr Cardiol* 2014; **35**:1246–1252.
- 172 Ganesh A, Kaye R, Cahill AM, *et al.* Evaluation of ultrasound-guided radial artery cannulation in children. *Pediatr Crit Care Med* 2009; **10**:45–48.
- 173 Ishii S, Shime N, Shibasaki M, Sawa T. Ultrasound-guided radial artery catheterization in infants and small children. *Pediatr Crit Care Med* 2013; **14**:471–473.
- 174 Min JJ, Tay CK, Gil NS, *et al.* Ultrasound- versus palpation-guided techniques for radial arterial catheterisation in infants under 12 months old: a randomised, controlled and patient-blinded trial. *Eur J Anaesthesiol* 2019; **36**:200–205.
- 175 Schwemmer U, Arzet H, Trautner H, *et al.* Ultrasound-guided arterial cannulation in infants improves success rate. *Eur J Anaesthesiol* 2006; **23**:476–480.
- 176 Ueda K, Puangsuwan S, Hove MA, Bayman EO. Ultrasound visual image-guided vs Doppler auditory-assisted radial artery cannulation in infants and small children by nonexpert anaesthesiologists: a randomized prospective study. *Br J Anaesth* 2013; **110**:281–286.
- 177 Oakley E, Wong AM. Ultrasound-assisted peripheral vascular access in a paediatric ED. *Emerg Med Australas* 2010; **22**:166–170.
- 178 Le CK, Lewis J, Steinmetz P, *et al.* The use of ultrasound simulators to strengthen scanning skills in medical students: a randomized controlled trial. *J Ultrasound Med* 2019; **38**:1249–1257.
- 179 Liu RB, Suwondo D, Donroe JH, *et al.* Point-of-care ultrasound: does it affect scores on standardized assessment tests used within the preclinical curriculum? *J Ultrasound Med* 2019; **38**:433–440.
- 180 Mayo PH, Beaulieu Y, Doelken P, *et al.* American College of Chest Physicians/La Société de Réanimation de Langue Française statement on competence in critical care ultrasonography. *Chest* 2009; **135**:1050–1060.
- 181 Killu K, Coba V, Mendez M, *et al.* Model point-of-care ultrasound curriculum in an intensive care unit fellowship program and its impact on patient management. *Crit Care Res Pract* 2014; **2014**:934796.
- 182 Fagley RE, Haney MF, Beraud AS, *et al.* Critical care basic ultrasound learning goals for American anesthesiology critical care trainees: recommendations from an expert group. *Anesth Analg* 2015; **120**:1041–1053.
- 183 Pustavoitau A, Blaivas M, Brown SM, *et al.* From the Ultrasound Certification Task Force on behalf of the Society of Critical Care Medicine: recommendations for achieving and maintaining competence and credentialing in critical care ultrasound with focused cardiac ultrasound and advanced critical care echocardiography. Society of Critical Care Medicine. <http://journals.lww.com/ccmjournal/Documents/Critical%20Care%20Ultrasound.pdf>. [Accessed 16 August 2019].
- 184 Arntfield R, Millington S, Ainsworth C, *et al.* Canadian recommendations for critical care ultrasound training and competency. *Can Respir J* 2014; **21**:341–345.
- 185 Schnobrich DJ, Mathews BK, Trappey BE, *et al.* Entrusting internal medicine residents to use point of care ultrasound: towards improved assessment and supervision. *Med Teach* 2018; **40**:1130–1135.
- 186 Feller-Kopman D. Ultrasound guided internal jugular access: a proposed standardized approach and implications for training and practice. *Chest* 2007; **132**:302–309.
- 187 Bodenham A. Ultrasound imaging by anaesthetists: training and accreditation issues. *Br J Anaesth* 2006; **96**:414–417.
- 188 Woo MY, Frank J, Lee AC, *et al.* Effectiveness of a novel training program for emergency medicine residents in ultrasound-guided insertion of central venous catheters. *CJEM* 2009; **11**:343–348.
- 189 Davidson IJ, Yoo MC, Biasucci DG, *et al.* Simulation training for vascular access interventions. *J Vasc Access* 2010; **11**:181–190.
- 190 Moureau N, Lamperti M, Kelly LJ, *et al.* Evidence-based consensus on the insertion of central venous access devices: definition of minimal requirements for training. *Br J Anaesth* 2013; **110**:347–356.
- 191 Sites BD, Spence BC, Gallagher JD, *et al.* Characterizing novice behavior associated with learning ultrasound-guided peripheral regional anesthesia. *Reg Anesth Pain Med* 2007; **32**:107–115.
- 192 Tan SJ, Chin KJ, Chan VWS. Developing a training program for peripheral nerve blockade. *Int Anesthesiol Clinics* 2010; **48**:1–11.
- 193 Sultan SF, Iohom G, Shorten G. Effect of feedback content on novices' learning ultrasound guided interventional procedures. *Minerva Anesthesiol* 2010; **76**:1269–1280.
- 194 Nifong TP, McDevitt TJ. The effect of catheter to vein ratio on blood flow rates in a simulated model of peripherally inserted central venous catheters. *Chest* 2011; **140**:48–53.
- 195 He YZ, Zhong M, Wu W, *et al.* A comparison of longitudinal and transverse approaches to ultrasound-guided axillary vein cannulation by experienced operators. *J Thorac Dis* 2017; **9**:1133–1139.